



BioBacta

Journal of Bioscience and Applied Research
<https://jbaar.journals.ekb.eg/>

SPBH

Evaluation of the renal protection conferred by amygdalin against animal growth regulator Boldjan induced renal toxicity and injury in male rats.

Sawsan Agbashee Alsadee

Department of Basic Sciences, College of Nursing, Misan University, Iraq

sawsanalsadee@gmail.com saw.alsadee@uomisan.edu.iq

DOI: 10.21608/jbaar.2024.354033

Abstract:

Among the supplements that athletes utilize most frequently are anabolic-androgenic steroids (AAS). Boldjan is an AAS drug used by young adults who want to look better and feel better about themselves and used in veterinary medicine. Thus, the goal of the current study was to investigate if amygdalin extract could protect male rats from kidney damage, oxidative stress, and toxicity caused by the anabolic steroid Boldjan. Four groups (Gp1, Control; Gp2, Amygdalin; Gp3, Boldjan; Gp4, Boldjan+ Amygdalin) were created out of forty mature male Wistar rats. When compared to control Gp, Boldjan significantly increased relative body weights (RBW), relative weights of the kidney, serum urea, creatinine, potassium ions, calcium ions, and chloride ions, and caused renal damage. It also significantly decreased sodium ions. By contrast, in post-treated rats Gp (Boldjan+Amygdalin), Amygdalin markedly restored the kidney damage generated by Boldjan. Amygdalin may be a useful prophylactic supplement to reduce kidney toxicity caused by Boldjan, perhaps through regulating oxidative stress reactions.

Key Words: Anabolic-androgenic steroids, Boldjan, Amygdalin, kidney toxicity.

Introduction

A class of man-made compounds called AAS is produced from testosterone and its precursors [1]. Abuse of AAS has been linked to many illnesses, including kidney damage [2], cardiovascular disorders [3-5], liver dysfunction [6-8]. and testicular problems [9,10]. Injectable AAS can help athletes build and grow more muscle directly [5,11]. Boldenone, Ultragan, Rexobol, Mibolerone, Ultima-Tren E, Neurabol, Stanozolol, Equigan, Trenbolone, Equipoise, Winsol, Rexogin, Ganabol, Trenorol and Boldjan are well-known injectable AAS that developed mainly for veterinary use by athletes to enlarge their muscles and by women in a variety of cosmetics to enhance the volume of their

lips, cheeks, buttocks, and breasts [10,12]. Moreover, humans may be indirectly affected by consuming meat from animals that have received AAS treatment. Veterinarians and young people looking to put on muscle and gain power use a new AAS medication called Boldjan. AAS has two anabolic effects: it promotes cell proliferation in the first place, and it improves male characteristics by having androgenic effects [13,14]. AAS has been classed as a Schedule III medication and applies to several veterinary products [1,15].

Prunus armeniaca (apricot), Prunus persica (peach), and Prunus amygdalus var. amara are just a few of the Rosaceae fruit kernels that naturally contain cyanides, of which amygdalin, formerly known as

laetrile, is one of numerous nitrilosides [16,17]. The two glucose molecules that make up amygdalin are hydrocyanic acid, an anti-neoplastic substance, and benzaldehyde, which has an analgesic effect. ages [18-20]. The oil obtained from kernels of apricots is essentially rich in oleic, linoleic acids and α -, γ - and δ -tocopherols [21,22]. Vitamin B17 (VitB17) is extracted from the kernels of apricots, and it is one of many nitrilosides [23]. Vitamin B17 has appeared in several pharmacological properties including antimicrobial anticancer, anti-inflammatory activities, and antioxidant [24,25]. AAS has been utilized dramatically in recent years, particularly by young adults who want to improve their appearance and boost their self-esteem, therefore; the objective of the present investigation was to examine the preventative effects of amygdalin extract against AAS Boldjan-induced kidney toxicity in male rats.

Materials and Methods

Chemical and reagent

The Boldjan (50 mg/ml) vial was acquired from Laboratorios-Tornel Comp. located in Holland. Amygdalin was purchased from Amazon for a natural oils Company with a dose of 100 mg/kg body weight.

Experimental design

Forty male Wistar rats, a weight of approximately 150g, were used for the experiments and obtained from our university farm. The male rats were housed in the laboratory room for seven days before the start of the research and provided with a standardized diet ad libitum. Following two weeks of acclimation, rats were divided into four groups (Gps; each with ten animals).

First Gp: Control: This group of rats won't get any medicine.

Second Gp: The Amygdalin involved giving animals an intramuscular injection of Amygdalin (100 mg/kg body weight/day) twice a day for two weeks.

Third Gp: Boldjan; rats receive an intramuscular Boldjan injection (10 mg/Kg BW/week) for four weeks.

Fourth Gp: Injectable rats treated with Boldjan and subsequently with Amygdalin (Boldjan+Amygdalin); rats received intramuscular injections of Boldjan for four weeks, followed by two weeks of Amygdalin treatment.

Following a 10- to 12-hour fast, rats from each group were fully necropsied and put to sleep using sodium pentobarbital IP after the experiment. The rats' inferior vena-cava was used to draw blood samples, which were then placed in non-heparinized glass tubes. The blood was then incubated for ten minutes at room temperature, allowed to clot, and then centrifuged for ten minutes at 3000 r.p.m. to extract the serum. The serum was then separated and stored in a clean plastic vial with a stopper at -80°C until the serum parameters were estimated. Each group's kidney was divided in half and preserved at -80°C while the other half was fixed in 10% buffer formalin for histological analyses.

Kidney functions and Electrolyte estimation:

Following Patton and Crouch, urea and creatinine levels were measured [26]. Using commercial kits of Indian Sensa core electrolyte, the method developed by Abd Eldaim et al. [27] was surveyed to measure the amounts of potassium (K^{+}), calcium (Ca^{++}), sodium (Na^{+}), and chloride (Cl^{-}) ions.

Histopathological investigation:

The kidney was promptly removed from each group, cleaned in 0.9 saline solutions, and preserved in 10% neutral buffered formalin. As per Tousson's standard protocol, sections were stained with Ehrlich's hematoxylin and counter-stained with eosin [28].

Statistical analysis:

Using one-way ANOVA for statistical analysis and data expressed as mean values \pm SE, it was possible to ascertain whether there were any significant

differences between the experimental groups. For biochemical data, statistical significance was determined and denoted by $p < 0.05$. All statistical analyses were performed using SPSS software.

Results:

As represented in Table 1 revealed that treatments of rats with Boldjan induced a significant elevation in relative body weight (RBW) and relative weights of kidney (RKW) as compared to control Gp. Meanwhile, post-treatment of Boldjan with Amygdalin (Boldjan+Amygdalin) induced a significant depletion in relative body weight (RBW) and relative weights of kidney (RKW) as compared to Boldjan Gp.

Effect of Boldjan and Amygdalin on Kidney Functions:

As represented in Table 2 revealed that treatments of rats with Boldjan induced a significant elevation

in serum creatinine and urea as compared to control Gp. On the other hand, post-treatment of Boldjan with Amygdalin (Boldjan+Amygdalin) induced a significant depletion in serum creatinine and urea as compared to Boldjan Gp.

Effect of Boldjan and Amygdalin on electrolytes levels

As represented in Table 3 revealed that; treatments of rats with Boldjan induced a significant elevation in serum potassium ions, calcium ions, chloride ions, and a significant depletion in serum sodium ions as compared to control Gp. On the other hand, post-treatments of Boldjan with Amygdalin (Boldjan+Amygdalin) induced a significant depletion in serum potassium ions, calcium ions, and chloride ions and a significant elevation in serum sodium ions as compared to Boldjan Gp.

Table 1: Changes in RBW and RKW in different groups.

	RBW (g/100 g)	RKW (g/100 g)
Control	25.8 [#] ± 1.70	1.55 [#] ± 0.15
Amygdalin	24.5 [#] ± 1.75	1.48 [#] ± 0.20
Boldjan	39.0* ± 2.15	2.35* ± 0.14
Boldjan+Amygdalin	33.5 ^{#*} ± 2.41	1.62 [#] ± 0.18

Data are expressed as mean ± SE of 10 observations. *Significant difference from the control at $p < 0.05$, [#]Significant difference from the Boldjan at $p < 0.05$.

$$\text{Relative organ weight} = \frac{\text{Organ weight}}{\text{Body weight}} \times 100$$

Table 2: Variations in kidney function levels in different Gps.

	Creatinine (mg/dl)	Urea (mg/dl)
Control	0.61 [#] ± 0.04	23.6 [#] ± 1.18
Amygdalin	0.57 [#] ± 0.02	21.0 [#] ± 0.92
Boldjan	1.05* ± 0.09	47.5* ± 2.25
Boldjan+Amygdalin	0.75** ± 0.05	33.1** ± 1.60

Data are expressed as mean ± SE of 10 observations. * Significant difference from the control at $p < 0.05$, [#] Significant difference from the Boldjan at $p < 0.05$.

Table 3: Changes in serum electrolytes level in different Gps.

	K ⁺ (mmol/l)	Na ⁺ (mmol/l)	Ca ⁺⁺ (mmol/l)	Cl ⁻ (mmol/l)
Control	3.95 [#] ± 0.19	137.0 [#] ± 10.4	1.21 [#] ± 0.08	100.5 [#] ± 7.25
Amygdalin	3.91 [#] ± 0.22 ^b	136.2 [#] ± 10.1	1.23 [#] ± 0.09	100.3 [#] ± 7.07
Boldjan	4.41* ± 0.48	125.5* ± 9.8	1.27* ± 0.12	114.0* ± 6.50
Boldjan+Amygdalin	4.03 [#] ± 0.35	133.6 [#] ± 10.5	1.22 [#] ± 0.08	110.8* [#] ± 8.66

Data are expressed as mean ± SE of 10 observations. * Significant difference from the control at p < 0.05, [#] Significant difference from the Boldjan at p < 0.05.

Kidney structure investigation:

Renal corpuscles and proximal and distal convoluted tubules were among the completely normal components of the renal cortex that were visible in kidney slices from the control and amygdalin groups (Figs. 1A&1B). The kidney sections in the Boldjan group showed significant degeneration of the renal tissues, hemorrhage, and considerable glomerular necrosis, and most of the glomeruli appeared to have lost their attachments (Fig. 1C&1D). However, after receiving amygdalin treatment, Boldjan showed a modest recovery with slight deteriorated renal tubules, mild glomeruli atrophy, and mild leucocytic infiltrations (Fig. 1E&1F),

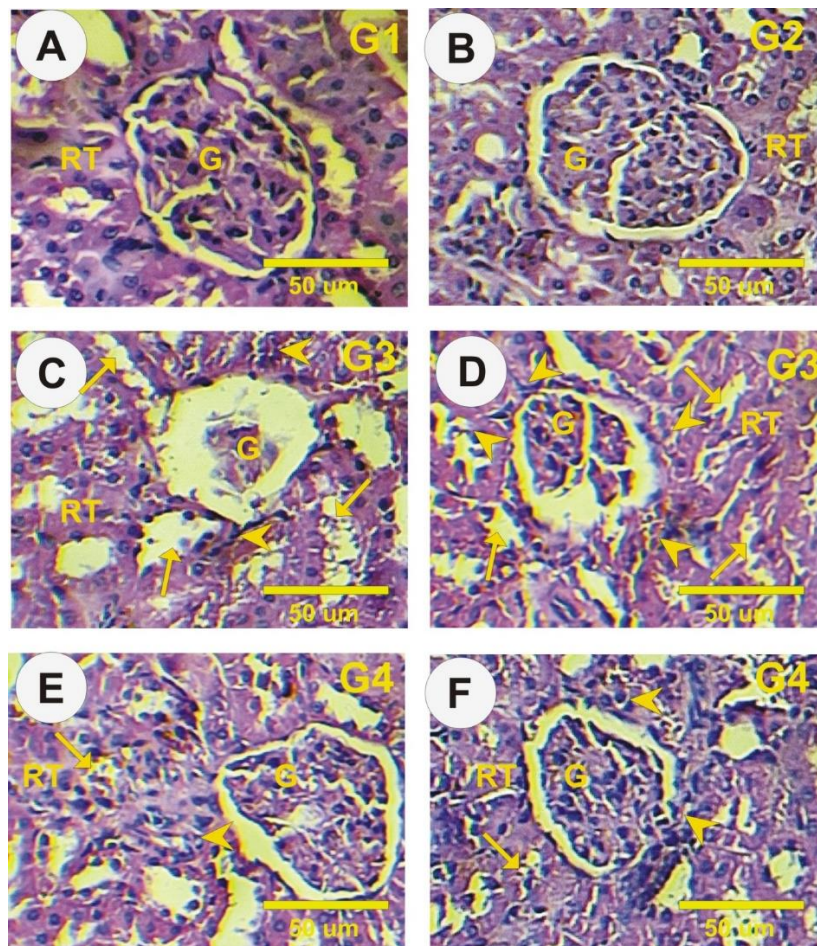


Figure 2: Haematoxylin & Eosin-stained kidney sections. **A&B:** Kidney sections in control and Amygdalin Gps showing a normal structure of glomeruli (G) and renal tubules (RT). **C&D:** Kidney sections in Boldjan Gp exposed marked damage and most of the glomeruli (G) seemed to have lost their attachments, marked glomerular necrosis, degenerated to the renal tissues (arrows), hemorrhage and leucocytic infiltrations (arrowheads). **E&F:** Kidney sections in post-treated Boldjan with Amygdalin exposed mild glomeruli (G) atrophy, mild leucocytic infiltrations (arrowheads), and moderate degenerated renal tubules (arrows).

Discussion

Naturally occurring, anabolic hormones like testosterone promote protein synthesis within cells. The goal of the current study was to determine whether amygdalin extract could protect male rats against renal damage caused by Boldjan. According to the current findings, male rats given the anabolic steroid Boldjan intramuscularly showed a significant increase in their relative body weight rate and kidney weights when compared to the control group. However, these increases were decreased when the rats were given amygdalin along with Boldjan. In accordance with Hoseini et al. [29], mice's body and kidney weight increased in response to nandrolone decanoate. The present findings are consistent with the findings of Holt et al. [30], who found that the anabolic steroid methenolone enanthate increased the growing rat's rate of weight gain and kidney weight. Additionally, the current findings corroborate the findings of Hussain et al. [6], who found that injections of boldjan considerably raised the body weight and total protein concentrations in male rabbits.

The present findings, however, contradict the findings of Oda and El-Ashmawy [31], who found no evidence of a substantial effect of the anabolic steroid boldenone on body weight or weight increase. The present findings corroborate those of Alm-Eldeen and Tousson [2], who report that an injection of the growth promoter Boldenone resulted in a marked decrease in glomerulus mass, which was followed by a widening of the mesangial regions. Our findings concur with those of Felemban et al. [20], who found that vitamin B17 reduces the body and testicular weight and

lessens the reproductive damage caused by methotrexate.

According to the current findings, rats given a Boldjan injection showed a substantial decrease in serum sodium ions as well as a significant increase in serum urea, creatinine, K, and Cl ions when compared to control Gp. As opposed to Boldjan Gp, post-treatments with amygdalin caused a notable decrease in serum creatinine, urea, K ions, Ca ions, and Cl ions as well as a notable increase in serum Na. According to these results, the growth promoter boldenone undecylenate may be misused, which could result in ongoing harm to the structures and functioning of the kidneys and the development of progressive renal disorders.

The current findings are consistent with those of Alm-Eldeen and Tousson [2], who report that injections of the growth promoter Boldenone resulted in a large increase in the amounts of creatine, urea, and total protein in male rabbits as well as a significant drop in the A/G ratio. These findings are consistent with those of Urhausen et al. [32] who found that intramuscular injections of boldenone undecylenate greatly improved the renal functions of weaned male lambs. Our findings also corroborated those of Tousson et al. [5], who discovered that injections of the growth promoter boldenone in rabbits caused damage to the kidneys and liver.

The current findings are consistent with the findings of Daher et al. [33] who showed that acute renal injury was caused by anabolic steroids, together with elevated serum urea, creatinine, and calcium ion levels. In contrast to the current findings, Gabr et al [34]. observed that intramuscular boldnone injection

dramatically reduced urea levels. The noted reduction in Na⁺ and a significant increase in K⁺ levels following Boldjan injection could perhaps be attributed to inhibition of the Na⁺/K⁺ ATPase pump, a crucial mechanism for maintaining Na⁺ and K⁺ equilibrium in eukaryotic cells. Overdosing on steroids inhibits Na⁺/K⁺ATPase and its signaling pathways, which raises intracellular Ca²⁺ and Na⁺ levels. The changes in electrolyte balance that are currently observed are consistent with the findings of earlier studies by Elmasry et al. [10] and Tousson et al. [4]. Furthermore, it has been proposed that glomerular hyperfiltration and elevated body mass are the root causes of AAS-induced direct glomerular toxicity [35]. Both hypophosphatemia and elevated uric acid contribute to the increased urea level in serum [34]. Because AASs cause an increase in muscle mass, they also raise the body's creatinine level. These findings are consistent with those of Mutar et al. [17] who report that vitamin B17 significantly increased calcium and sodium ion levels while significantly decreasing urea, creatinine, K, and Cl levels. Additionally, our findings are consistent with Guo et al. [36] findings that amygdalin improves the biochemical parameters in chronic kidney disease and suppresses renal fibrosis.

The current findings showed that the injection of Boldjan caused substantial glomerular necrosis, atrophy, and degeneration of the renal tissues and that treating Boldjan with amygdalin resulted in a moderate improvement in these abnormalities in the structure of the kidneys. Our findings concur with those of Tousson [28], who noted that injections of the growth-promoting drug boldenone in rabbits

can cause kidney damage. Our findings also corroborate the findings of Hoseini et al. [29] and Tousson et al [37], which showed that nandrolone decanoate caused renal impairment in mice. Treatment with herbal medicine improved kidney function and structure [38]. Also, Tsitsimpikou et al. [39] reported that; long-term nandrolone decanoate adminis induced renal toxicity and damage. Current results revealed that; treatments of Boldjan with amygdalin improved the damage in kidney structure after Boldjan treatments.

Conclusion

In conclusion, Boldjan injection in male rats induced renal toxicity and injury and the treatments with Amygdalin (Boldjan+Amygdalin) markedly restored the kidney damage generated by Boldjan. Amygdalin may be a useful prophylactic supplement to reduce kidney toxicity caused by Boldjan, perhaps through regulating oxidative stress reactions.

Acknowledgments

I would like to thank Prof. Dr. Ehab Tousson (Tanta University, Egypt) for his comments on an earlier version of this manuscript.

Funding: No fund.

Authors' contributions

Sawsan Alsadee conceptualized the research idea, and data analysis, wrote and edited the manuscript, and approved the final manuscript.

Availability of data and materials

All data generated or analyzed during this study are included in this published article. If detailed data are required, they can contact the correspondence of the study, Sawsan Alsadee (Email address: sawsanalsadee@gmail.com).

Declarations

Ethics approval and consent to participate.

Consent for publication:

Not applicable

Competing interests

The author declares that has no competing interests.

References

- 1 Ayubi N, Kusnanik NW, Herawati L, Komaini A, Cholik T, Syafawi A. Abuse of Anabolic-Androgenic Steroids and Adverse Effects on Human Organ Health: A Review. *Biointerface Res Appl Chem.* 2023;13(3):1-1.
- 2 Alm-Eldeen A, Tousson E. Deterioration of Glomerular Endothelial Surface Layer and the Alteration in the Renal Function after a Growth Promoter Boldenone Injection in Rabbits. *Hum. Exp. Toxicol.* 2012; 31: 465–472.
- 3 Tousson E, El-Moghazy M, Massoud A, El-Atrash A, Sweef O, Akel A. Physiological and biochemical changes after boldenone injection in adult rabbits. *Toxicol. Ind. Health* 2016; 32: 177–182.
- 4 Tousson E, Elgharabawy RM, Elmasry TA. Grape seed proanthocyanidin ameliorates cardiac toxicity induced by boldenone undecylenate through inhibition of NADPH oxidase and reduction in the expression of NOX2 and NOX4. *Oxidative medicine and cellular longevity.* 2018; 2018. Article ID 9434385, 12 pages, <https://doi.org/10.1155/2018/9434385>
- 5 Fadah K, Gopi G, Lingireddy A, Blumer V, Dewald T, Mentz RJ. Anabolic androgenic steroids and cardiomyopathy: an update. *Frontiers in Cardiovascular Medicine.* 2023;10.
- 6 Hussain EM, Alkadhimi SM, Neamah AM, Tousson E. Beneficial role of amygdalin extracts against animal growth regulator Boldjan induced cardiac toxicity, injury and oxidative stress in male rats. *Toxicology Research,* 2024; 13(2), p.tfae042.
- 7 Frankenfeld SP, Oliveira LP, Ortenzi VH, Rego-Monteiro IC, et al. The anabolic androgenic steroid nandrolone decanoate disrupts redox homeostasis in liver, heart and kidney of male Wistar rats. *PloS one.* 2014; 9: e102699. doi: 10.1371/journal.pone.0102699
- 8 Bond P, Llewellyn W, Van Mol P. Anabolic androgenic steroid-induced hepatotoxicity. *Medical Hypotheses.* 2016 Aug 1; 93:150-3.
- 9 Tousson E, El-Moghazy M, Massoud A, Akel A. Histopathological and immunohistochemical changes in the testes of rabbits after injection with the growth promoter boldenone. *Reprod. Sci.* 2012, 19: 253–259.
- 10 Elmasry TA, Al-Shaalan NH, Tousson E, El-Morshedy K, Al-Ghadeer A. Star Anise Extracts Modulation of Reproductive Parameters, Fertility Potential and DNA Fragmentation Induced by Growth Promoter Equigan in Rat Testes. *Braz. J. Pharm. Sci.* 2018; 54: doi:10.1590/s2175-97902018000117261
- 11 de Oliveira VG, Justus JS, Portela LV, Rodolphi MS. Synaptic and Extrasynaptic Mitochondria: Features and Impact of High Anabolic-Androgenic Steroids Use. In *Handbook of Substance Misuse and Addictions: From*

- Biology to Public Health 2022; (pp. 1-21). Cham: Springer International Publishing.
- 12 Getabalew M, Alemneh T, Zewdie D. Types and uses of growth promoters in beef cattle. *J Vet Med Sci*. 2020 Jul 22; 3(1):5.
- 13 Perry JC, Schuetz TM, Memon MD, Faiz S, Cancarevic I. Anabolic steroids and cardiovascular outcomes: the controversy. *Cureus*. 2020 Jul 22;12(7).
- 14 Seara FA, Olivares EL, Nascimento JH. Anabolic steroid excess and myocardial infarction: From ischemia to reperfusion injury. *Steroids*. 2020 Sep 1; 161:108660.
- 15 Albaz HA, Elmesallamy GE, El-Akabawy N, Abaza M. Whey protein and anabolic steroids: current trend and future potential effect on the heart. *Biochemical, histological, and immunohistochemical study. Egyptian Society of Clinical Toxicology Journal*. 2023 Jun 1;11(1):107-29.
- 16 Hasan AF, Alankooshi AA, Abbood AS, Dulimi AG, et al. Impact of B-Glucan Against Ehrlich Ascites Carcinoma Induced Renal Toxicity in Mice. *OnLine Journal of Biological Sciences*, 2023; 23(1): 103-108. <https://doi.org/10.3844/ojbsci.2023.103.108>
- 17 Mutar TF, Tousson E, Hafez E, Gazia MA, Salem SB. Ameliorative effects of vitamin B17 on the kidney against Ehrlich ascites carcinoma induced renal toxicity in mice. *Environmental Toxicology*. 2020 Apr;35(4):528-537.
- 18 El-Masry T, Al-Shaalan N, Tousson E, Buabeid M, Al-Ghadeer A. Potential therapy of vitamin B17 against Ehrlich solid tumor induced changes in Interferon gamma, Nuclear factor kappa B, DNA fragmentation, p53, Bcl2, survivin, VEGF and TNF- α Expressions in mice. *Pakistan journal of pharmaceutical sciences*. 2020 Jan 3;33.
- 19 El-Masry TA, Al-Shaalan NH, Tousson E, Buabeid M, Alyousef AM. The therapeutic and antineoplastic effects of vitamin B17 against the growth of solid-form Ehrlich tumours and the associated changes in oxidative stress, DNA damage, apoptosis and proliferation in mice. *Pak. J. Pharm. Sci*. 2019 Nov 1;32(6):2801-10
- 20 Felemban SG, Aldubayan MA, Alhowail AH, Almami IS. Vitamin B17 ameliorates methotrexate-induced reproductive toxicity, oxidative stress, and testicular injury in male rats. *Oxidative medicine and cellular longevity*. 2020 Oct 27;2020.
- 21 Tousson E, Hafez E, Gazia MM, Salem SB, Mutar TF. Hepatic ameliorative role of vitamin B17 against Ehrlich ascites carcinoma-induced liver toxicity. *Environmental Science and Pollution Research*. 2020; 27:9236–9246
- 22 Kumari N, Kumar M, Puri S, Baohong Z, Rais N, Pundir A, Chandran D, Raman P, Dhupal S, Dey A, Senapathy M. Peach (*Prunus persica* (L.) Batsch) seeds and kernels as potential plant-based functional food ingredients: A review of bioactive compounds and health-promoting activities. *Food Bioscience*. 2023 Jul 5:102914.

- 23 Abdaulmoneam DM, Bashir MH, El Baz DA. Effect of vitamin B17 (amygdalin) found in apricot kernel on the irradiated salivary glands of albino rats. *Dental and Medical Problems*. 2023 Jul 1;60(3):473-81.
- 24 El-Desouky MA, Fahmi AA, Abdelkader IY, Nasraddin KM. Anticancer effect of amygdalin (vitamin B-17) on hepatocellular carcinoma cell line (HepG2) in the presence and absence of zinc. *Anti-Cancer Agents in Medicinal Chemistry (Formerly Current Medicinal Chemistry-Anti-Cancer Agents)*. 2020 Mar 1;20(4):486-94.
- 25 Elmalla A, Elmetwalli A, Rizk ME, Salama AF. The effect of vitamin B17 on cardiomyopathy against Ehrlich tumor development in female mice. *Biochemistry Letters*. 2021 Dec 1;17(1):69-76.
- 26 Patton CJ, Crouch SR. Spectrophotometric and kinetics investigation of the Berthelot reaction for the determination of ammonia. *Analytical chemistry*. 1977; 49(3):464-9.
- 27 Abd Eldaim MA, Tousson E, El Sayed IE, Awd WM. Ameliorative effects of *Saussurea lappa* root aqueous extract against Ethephon-induced reproductive toxicity in male rats. *Environmental toxicology*. 2019 Feb;34(2):150-9.
- 28 Tousson E. Histopathological alterations after a growth promoter boldenone injection in rabbits. *Toxicology and industrial health*. 2016 Feb;32(2):299-305.
- 29 Hoseini L, Roozbeh J, Sagheb M, Karbalay-Doust S, Noorafshan A. Nandrolone decanoate increases the volume but not the length of the proximal and distal convoluted tubules of the mouse kidney. *Micron*. 2009 Feb 1;40(2):226-30.
- 30 Holt TL, Ward LC, Thomas BJ, Davey JF, Shepherd RW. The effect of an anabolic steroid, methenolone enanthate, on growth, body composition and skeletal muscle protein synthesis in the growing rat. *Nutrition Research*. 1990 May 1;10(5):535-45.
- 31 Oda SS, El-Ashmawy IM. Adverse effects of the anabolic steroid, boldenone undecylenate, on reproductive functions of male rabbits. *International journal of experimental pathology*. 2012 Jun;93(3):172-8.
- 32 Urhausen A, Torsten A, Wilfried K. Reversibility of the Effects on Blood Cells, Lipids, Liver Function and Hormones in Former Anabolic-Androgenic Steroid Abusers. *J. Steroid Biochem. Mol. Biol.* 2003; 84: 369–375. doi:10.1016/s0960-0760(03)00105-5
- 33 Daher EF, Júnior GBS, Queiroz AL, Ramos LM, Santos SQ, Barreto DM, Guimarães AAC, Barbosa CA, Franco LM, Patrocínio RM. Acute kidney injury due to anabolic steroid and vitamin supplement abuse: report of two cases and a literature review. *Int Urol Nephrol*. 2009; 41:717–23.
- 34 Gabr F, Abo El-Maaty T, Amal M, Aotifa AM. Effects of growth promoter boldenone undecylenate on weaned male lambs. *Nature and Science* 2009; 7: 61-69.
- 35 Sessa F, Salerno M, Bertozzi G, Cipolloni L, Messina G, Aromatario M, Polo L,

- Turillazzi E, Pomara C. miRNAs as novel biomarkers of chronic kidney injury in anabolic-androgenic steroid users: An experimental study. *Frontiers in Pharmacology*. 2020 Sep 16; 11:563756.
- 36 Guo J, Wu W, Sheng M, Yang S, Tan J. Amygdalin inhibits renal fibrosis in chronic kidney disease. *Molecular Medicine Reports*. 2013 May 1;7(5):1453-7.
- 37 Tousson E, Alm-Eldeen A, El-Moghazy M. p53 and Bcl-2 expression in response to boldenone induced liver cells injury. *Toxicology and Industrial Health* 2011;27(8): 711–8.
- 38 Hasan AF, Hameed HM, Tousson E, Massoud A, Atta F, Youssef H. Role of Oral Supplementation of Damiana (*Turnera diffusa*) Reduces the Renal Toxicity, Apoptosis and DNA Damage Associated with Amitriptyline Administration in Rats. *Biomedical and Pharmacology Journal*. 2022 Sep 29;15(3):1245-53
- 39 Tsitsimpikou C, Vasilaki F, Tsarouhas K, Fragkiadaki P, Tzardi M, Goutzourelas N, Nepka C, Kalogeraki A, Heretis I, Epitropaki Z, Kouretas D. Nephrotoxicity in rabbits after long-term nandrolone decanoate administration. *Toxicology Letters*. 2016 Sep 30; 259:21-7.