



Journal of Bioscience and Applied Research

JBAAR

WWW.JBAAR.ORG



Effect of chitosan nanoparticles on haloperidol drug-induced hepatotoxicity in albino rats: Light and Electron Microscopic study

Sahar A. Sabry¹; Samia M. Sakr² and Hassan M. Ibrahim³

^{1&2} Department of Biological and Geological Sciences, Faculty of Education, Ain Shams University

³ Pre-Treatment & Finishing of Cellulosic Fibers, Textile Research Division, National Research Centre, Dokki, Giza, Egypt.

(Corresponding author e.mail: saharsabry84@yahoo.com)

Abstract

Haloperidol (HP) is a widely used neuroleptic drug for the treatment of acute and chronic psychosis. The present study was carried out to investigate the effect of haloperidol on the liver of rats and the possible preventive effect of chitosan nanoparticle. Thirty two adult male rats were used in the present study. They were allocated into four groups. The first group served as control and was injected i.p. with 1mg/kg saline solution. The second group, each rat received a single (i.p.) injection of (2 mg/kg b.wt.) chitosan nanoparticles, each animal of third group given 0.3mg/ml/kg haloperidol while in the fourth group each rat received 0.3 mg/ml/kg haloperidol carried on nanoparticles daily for 21 days. Histological examination of liver sections of haloperidol- treated rats revealed destruction of the normal pattern of the hepatic lobules. The hepatic cells appeared with fatty degeneration and vacuolation of hepatocytes. The nuclei of hepatocytes exhibited noticeable signs of deterioration; pyknosis, karyorrhexis and karyolysis. Congestion of blood vessels was also detected and the portal areas were invaded by inflammatory lymphocytes. On the other hand, the liver sections of rats treated with haloperidol carried on nanoparticles showed minimizing the toxic effects of haloperidol alone. Electron microscopic investigation of hepatocytes of haloperidol-treated rats revealed conspicuous alterations, represented by aggregation of the rough endoplasmic reticulum in clumps and the mitochondria underwent swelling with obvious condensation of their matrices by materials that displayed high electron density and some of them lost their cristae. In conclusion: this study showed that when

haloperidol carried on nanoparticles it decreased the destructive progress of haloperidol on the liver of rats.

Keywords: Nanoparticles, Haloperidol, liver, Rats, Histology

1 Introduction

Antipsychotics are a heterogeneous group of substances characterized by a superior efficiency against negative, positive and affective symptoms in schizophrenia and by an adequate cognitive protection. Side effect profile was an important element of these substances in the first line of treatment of psychotic disorders (Olofinjana and Taylor 2005 ; Leucht et al., 2009). Therapeutic properties of this group of antipsychotics are reflected by a good therapeutic compliance and an adequate level of patients' quality of life.

One of these drugs is Haloperidol (HP), which is a widely used neuroleptic drug for the treatment of acute and chronic psychosis, e.g., schizophrenia. HP belongs to the butyrophenone group and is thought to exert its clinical effect through cerebral dopamine D2-receptors and α -receptors. Chronic treatment with neuroleptics increases free radical production and oxidative stress. Chronic use of neuroleptics is also reported to decrease the activity of antioxidant defense enzymes, superoxide dismutase (SOD) and catalase (Naidu et al., 2003). However, sufficient data emerged warning about the risk of side effects and imposing a clinical and biological monitoring of patients

under therapy with atypical antipsychotics (Davis et al., 2003; Lieberman et al., 2005). Complex interdisciplinary evaluations are necessary both on short and long term (Cohn and Sernyak 2006; Smith et al., 2008).

Nanomedicine is the medical application of nanotechnology (Robert and Freitas 1999). Nanomedicine ranges from the medical applications of nanomaterials and biological devices, to nanoelectronic biosensors, and even possible future applications of molecular nanotechnology such as biological machines. Functionalities can be added to nanomaterials by interfacing them with biological molecules or structures. The size of nanomaterials is similar to that of most biological molecules and structures; therefore, nanomaterials can be useful for both in vivo and in vitro biomedical research and applications. Thus far, the integration of nanomaterials with biology has led to the development of diagnostic devices, contrast agents, analytical tools, physical therapy applications, and drug delivery vehicles. Nanomedicine seeks to deliver a valuable set of research tools and clinically useful devices in the near future (Freitas 2005 and Wagner et al., 2006).

The use of materials in nanoscale provides freedom to modify fundamental properties like blood circulation half-life, drug release characteristics, and immunogenicity. In the last two decades, a number of nanoparticle-based therapeutic and diagnostic agents have been developed for the treatment of diabetes, pain, cancer, allergy, asthma, infections, and so on (Brannon-Peppas and Blanchette 2004; Kawasaki and Player 2005). These nanoscale agents may provide more effective and more convenient routes of administration, lower therapeutic toxicity, extend the product life cycle, and ultimately reduce health-care costs. Also nanoparticles allow targeted delivery in addition to control release. beside improves the solubility of poorly water-soluble drugs, prolongs the half-life of drug systemic circulation by reducing immunogenicity, releases drugs at a suitable rate or in an environmentally responsive manner which lowers the frequency of administration, delivers drugs in a target manner to minimize systemic side effects, and suppress drug resistance. Also many advantages of nanoparticle-based drug delivery have been recognized. As a result of the later, a few pioneering nanoparticle-based therapeutic products have been introduced into the pharmaceutical market, and numerous under clinical testing or are entering the pipeline (Groneberg et al., 2006; Emerich and Thanos 2007).

For this reason, the present study aimed to achieve an experimental study to record the impacts of haloperidol on liver and also to illustrate the possible role of nanoparticles in minimizing the hepatotoxicity of haloperidol.

2 Materials and Methods

a. The applied drugs

Haloperidol (trade name haloperidol 5mg/ml) is a phenyl-piperidiny-butyrophenone that is used primarily to treat schizophrenia and other psychoses. It is a potent

antiemetic and is used in the treatment of intractable hiccups. It is manufactured by Patriot Pharmaceuticals LLC and available in the form of vials.

b. Preparation of chitosan nanoparticles

Chitosan nanoparticles were prepared based on the modified ionotropic gelation (Ibrahim et al., 2017). Briefly, Chitosan was dissolved in 1% (v/v) acetic acid and leaving it under stirring for 24 hr. The pH was adjusted to pH 5.5 with 0.01N NaOH. TPP was dissolved separately in deionized water to final concentration of 0.1 mg/ml. Then, the TPP solution was added to the chitosan solution drop wise at different TPP:chitosan ratios under vigorous magnetic stirring at room temperature. The resulting suspension was then left under Ultrasonication for 45 min.

c. Preparation of Haloperidol-loaded chitosan nanoparticles:

Different concentrations of the antibiotic dissolved in distilled water was added to nano chitosan solution in the same molar ratio with stirring for 20 min. and the resulting suspension was then left under ultra-sonication for 45 min. then finally stirring for another 20 min., to obtain a final haloperidol concentration (0.05, 0.1, .15, 0.2, 0.5% mg/ml) (Ibrahim et al., 2017).

d. The experimental animals and design

Thirty two adult male Wistar rats, weighing 150 ± 20 g were obtained from Theodor Bilharz Research Institute (TBRI), Imbaba, Guiza, A.R. Egypt and acclimatized in an environmentally control room for four weeks (12h light/12h dark cycle at temperature of 25 ± 2 oC). The animals were housed in wire meshed cages and were fed with commercial rat diet and water *ad libitum*. All diets were prepared weekly and stored at 4C°. The animals were allocated into four groups, each of 8 animals. The **first** group served as control and was injected i.p. with 1 ml/kg saline solution. The **second** group; each rat received a single i.p. injection of (2 mg/kg body weight) nano particles, each animal of the **third** group was given 0.3mg/ml/kg haloperidol while in the **fourth** group each rat received 0.3mg/ml/kg haloperidol carried on nanoparticles daily for 21 days. The dose of the drug was calculated according to Paget and Barnes (1964).

e. Histological and Ultrastructural Preparations

For light microscopic examination, small pieces of the liver of control and treated animals were fixed for 24 hours in aqueous Bouin's fixative. The specimens were then dehydrated, cleared in terpineol and embedded in paraffin wax. Sections of 5 μ m thickness were stained with haematoxylin and eosin, microscopically examined, and photomicrographs were made as required. For ultrastructural evaluation by transmission electron microscopy as described by Dykstra et al. (2002), freshly excised liver pieces were cut into very small pieces and fixed directly in cold 4FIG (i.e. 4% formalin+1% glutaraldehyde adjusted at pH 2.2) for 24 hours. Then, they were postfixed in 1% osmium tetroxide in 0.1 M phosphate buffer (pH 7.3), dehydrated in an ethanolic series culminating in 100% acetone, and infiltrated with epoxide resin. After polymerization overnight at 60 C, semi-thin sections (0.5 μ m) were stained with 1% toluidine blue in

sodium borate and examined with the light microscope. Ultrathin sections were cut, mounted on 200 mesh copper grids, and stained with uranyl acetate and lead citrate (Reynolds, 1963). The stained grids were examined and photographed by a JEOL –JEM-1400 EX- electron microscope, at the Regional Center for Mycology and Biotechnology (RCMB), Al-Azhar University.

3 Results

Histopathological observations

Group I: The control rats

The liver of the control rats showed the common characteristic lobular organization of the mammalian liver. Each lobule is formed of cords of hepatocytes radiating from a central vein. The hepatic cords are separated from each other by blood sinusoids lined with endothelial cells interspersed by Kupffer cells (Fig. 1). The hepatic lobules are separated by loose connective tissue containing at certain angles the portal triads including branches of the portal vein, hepatic artery and a narrow bile ductile.

Group II: Single injection nanoparticles-treated rats

Rats received a single intraperitoneal injection of nanoparticles showed moderate alterations in the hepatic tissues. Cytoplasmic vacuolation of some hepatocytes was noticed (Figs. 2 & 3). Dilatation of the hepatic sinusoids with swelling of Kupffer cells which markedly by increased in size and some of them were observed in the lumina of sinusoids (Fig. 3). The nuclei of hepatocytes still appeared nearly normal. (Figs. 2&3).

Group III: Haloperidol-treated rats

The examination of liver sections of rats treated daily with 0.3mg/kg. b.wt. of haloperidol for 21 days revealed a prominent destruction of the normal pattern of the hepatic lobules as well as disorganization of the hepatic strands (Fig.4). The hepatic cells reflected by fatty degeneration and vacuolation of some hepatocytes (Figs. 4-6). The nuclei of some hepatocytes exhibited noticeable signs of deterioration; pyknosis and karyolysis of the nuclei were also illustrated (Figs. 4&6). Congestion of blood vessels was indicated by the dilation of the central vein which contained stagnant hemolyzed red blood cells (Fig.5). The markedly dilated central veins possessed thickening of their endothelial lining (Fig.5). The portal areas were invaded by inflammatory lymphocytes (Fig.6).

Group IV: Haloperidol carried on nanoparticles-treated rats

The histological structure of the liver of most rats treated with haloperidol carried on nanoparticles manifested marked improvements against the damage displayed by haloperidol only. The hepatic cords were well organized and the cytoplasmic vacuolation disappeared (Figs.7&8). Most nuclei exhibited normal shape being spherical and centrally located (Fig. 8).

Ultrastructural observations

Group I: The control rats

Electron microscopic examination of the liver of the control rats revealed their normal ultrastructural appearance (Figs 9&10). The cytoplasm of hepatocytes contains numerous mitochondria dispersed all over the cytoplasm. The mitochondria are spherical or ovoid in shape with well developed cristae. The rough endoplasmic reticulum consists of closely packed parallel and flattened cisternae studded with ribosomes (Fig.9). Considerable electron-dense glycogen rosettes or granule are clearly detected in the cytoplasm of the hepatocytes (Fig.9). The nuclei of the hepatocytes are spherical, each with a distinct nuclear envelope, and the nucleoplasm shows aggregations of euchromatin and heterochromatin materials (Fig. 9). Hepatic sinusoids are localized between the hepatocytes and lined with Kupffer cells are also observed (Fig. 10).

Group II: Single injection nanoparticles-treated rats

Examination of the liver cells of rats received a single intraperitoneal injection of (2 mg/kg of b.wt.) of nanoparticles revealed marked cytopathological alterations (Figs. 11&12). Marked aggregation of the rough endoplasmic reticulum in clumps and the mitochondria underwent swelling with obvious condensation of their matrices by materials that displayed high electron density and some of them lost their cristae (Fig. 11). The nuclei of the hepatocytes showed degeneration of the chromatin materials (Fig.12). nano particles were distributed through the hepatocytes (Fig. 11). Figure 12 shows degenerated Kupffer cell with shrunk nucleus.

Group III: Haloperidol-treated rats

Severe consequences were evoked in the ultrastructure of the hepatocytes of rats treated with haloperidol. The cytoplasm of the hepatocytes showed conspicuous degeneration and vacuolation (Fig.13). The mitochondria underwent swelling with condensation of their matrices and some of them lost their cristae, fragmentation of rough endoplasmic reticulum into smaller stacks was also observed in the hepatocytes of this group (Fig. 13). There was hypertrophy of Kupffer cell. The nucleus appeared with an irregular nuclear envelope and the nucleoplasm showed clumps of heterochromatin adherent to the nuclear envelope (Fig. 14).

Group IV: Haloperidol carried on nanoparticles-treated rats

Treatment of rats of group IV with haloperidol carried on nanoparticles had resulted into marked improvement. As revealed in the electron micrographs of hepatocytes displayed in figure (15) show restoring the state of nearly normal appearance, where the cytoplasm of the hepatocytes show few damaged organelles. Their nuclei appear more or less damaged with minor contents of chromatin. Their nuclear envelope still showing obvious notching (Fig. 15). The hepatic cells contained numerous mitochondria exhibiting an almost normal appearance (Fig.15). The hepatic cells revealed well developed rough endoplasmic reticulum in the form of parallel and flattened cisternae (Fig. 15).

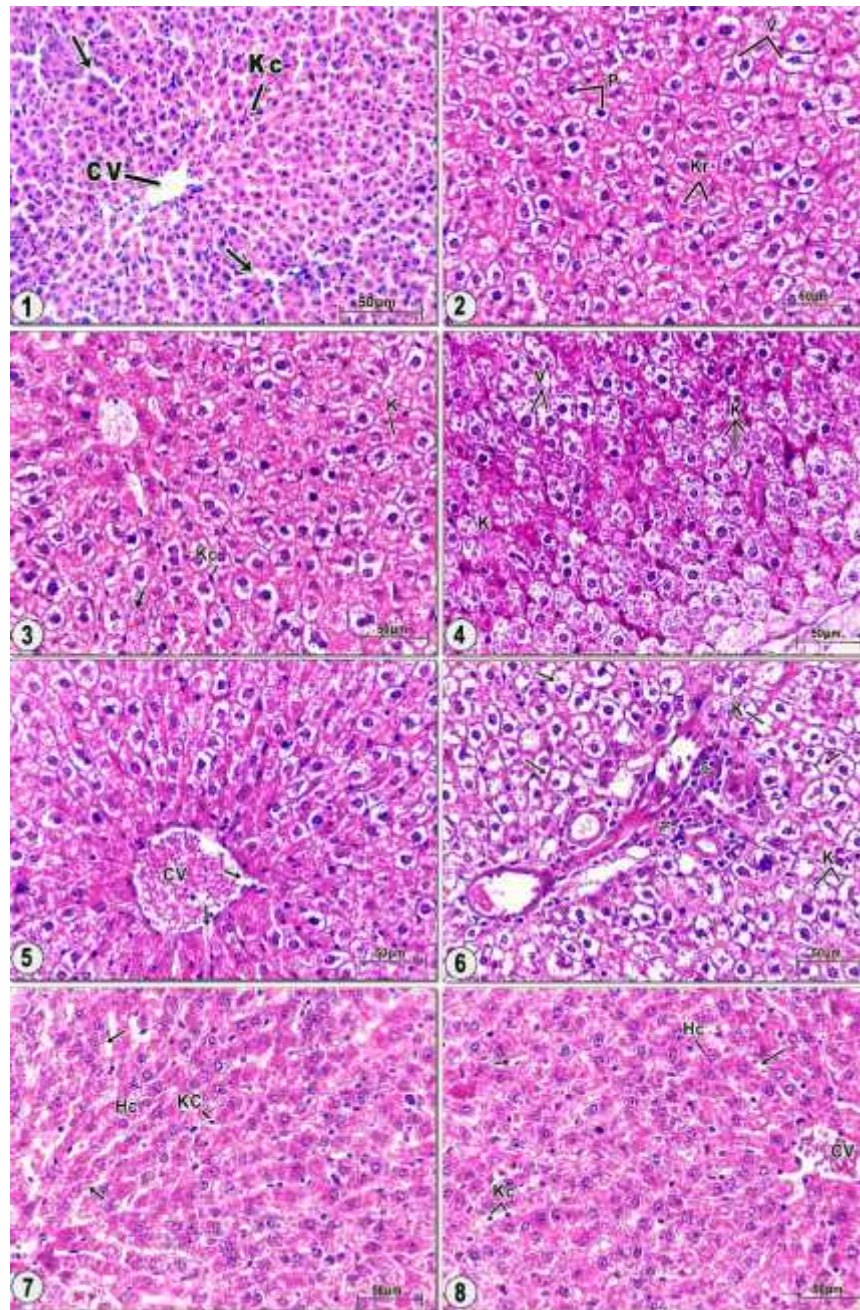


Fig. 1. Photomicrograph of liver sections of control rats, showing a network of hepatic strands consisting of hepatocytes, central vein (CV) and narrow hepatic sinusoids (arrows) being localized between these strands. Küpffer cells (KC) are also appeared.

Fig.(2). Showing cytoplasmic vacuolation (V) of some hepatocytes and the nuclei show pyknosis (P) and karyorrhexis (Kr) of their chromatin materials.

Fig.(3). Showing dilated hepatic sinusoids and swollen Kupffer cells (KC). Karyolysed nuclei (arrow) of some hepatocytes is also observed in this figure.

Fig.(4). Showing destruction of the hepatic strands and extensive cytoplasmic vacuolations (V) with marked karyolysis (K) of the nuclei of some hepatocytes.

Fig. (5). Showing dilated and congested central vein (CV) with erosion of its endothelial lining (arrows).

Fig. (6). Showing fatty changes in hepatocytes (arrows) with karyolysed (K) their nuclei. Notice inflammatory cells infiltration (*) in the vicinity of the portal area and thickening the endothelial lining of hepatic portal vein.

Fig. (7). Showing that the hepatocytes (HC) partly restored their normal configuration and their nuclei appeared nearly normal. Notice, dilatation of some hepatic sinusoids with swollen Kupffer cells (KC) pushed into the lumina of the sinusoids (arrows).

Fig. (8). Showing central vein (CV) surrounded by the hepatocytes (HC) partly restored their normal configuration. In addition to, dilatation of some hepatic sinusoids with swollen Kupffer cells (KC) pushed into the lumina of the sinusoids (arrows).

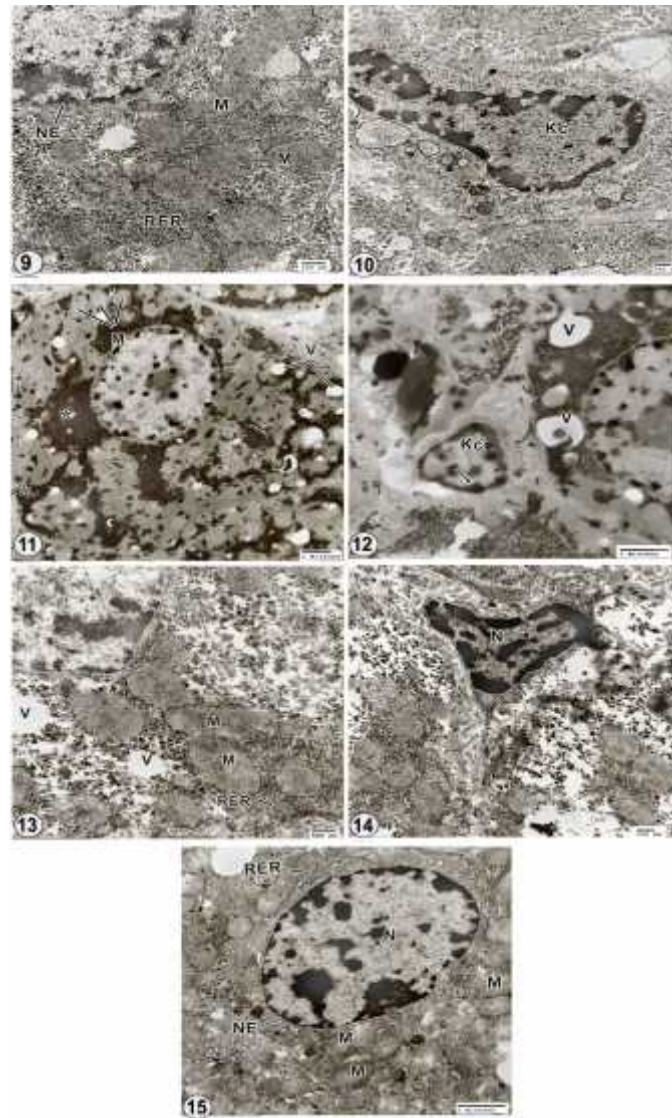


Fig. (9). Electron micrographs of liver sections of a control rat showing the cytoplasm of a hepatocyte contains various shapes of mitochondria (M), well developed rough endoplasmic reticulum (RER) and glycogen rosettes. Part of nucleus with its nuclear envelope (NE) is also observed.

Fig. (10). Showing the hepatic sinusoid separated from adjacent hepatocyte by the space of disse. Irregular microvilli extended from the hepatocyte surface into this space (*). The sinusoid is limited by a prominent Kupffer cell (KC).

Figs. (11&12). Electron micrographs of liver sections of rats received a single injection of 2 mg/ml b.wt. of nanoparticles.

Fig. (11). Showing swollen mitochondria (M) with obvious condensation of their matrices and some of them lost their cristae. Notice, the nanoparticles are distributed through the hepatocyte and its nucleus (*).

Fig. (12). Showing a dilated hepatic sinusoid with an activated Kupffer cell(KC). Condensed heterochromatin is found on the inner membrane of the nuclear envelope (arrow). Notice the presence of few vacuoles (V) in the cytoplasm of hepatocyte.

Figs. (13-14). Electron micrographs of liver sections of rats treated with 0.3mg/kg. b.wt. of haloperidol for 21 days.

Fig. (13). Showing that the cytoplasm of the hepatocytes contains vacuoles (V), marked swelling of mitochondria (M) which lost their internal ridges and fragmented rough endoplasmic reticulum (RER).

Fig. (14). Showing a Kupffer cell with pyknotic nucleus (N). Notice degenerated cytoplasm of the hepatocyte.

Fig. (15). Electron micrograph of liver sections of rats treated with 0.3mg/kg. b.wt. of haloperidol carried on nanoparticles, showing the hepatocytes partly restored their normal configuration with mitochondria (M) in the form of spherical configuration, rough endoplasmic reticulum (RER) localization near the nuclear envelope. The nucleus (N) with distinct nuclear envelope (NE) and nucleoplasm with euchromatin and heterochromatin.

4 Discussion

Antipsychotics remain the standard of care for individuals with schizophrenia, despite their association with adverse effects including extrapyramidal symptoms, metabolic syndrome and agranulocytosis. While the biological mechanisms underlying these side effects remain unsolved, it has been proposed that oxidative stress may play role in their development (Bogdan et al., 2011; Mondelli et al., 2013 and Andrezza et al., 2015).

The liver is the most suitable organ for testing the possible adverse effects of chemical or physical factors in the body, probably due to its role in detoxification and metabolism of a wide profile of chemicals (Yamazuki and Larusso, 1989).

The results of the present investigation clearly demonstrated that the application of Haloperidol (HP) to adult male rats induced conspicuous alterations in histological and fine structure of the liver tissue. The treatment with HP for 21 days revealed a prominent destruction of the hepatic strands. The hepatic cells reflected by fatty degeneration and vacuolation of some hepatocytes. The nuclei of some hepatocytes exhibited noticeable signs of deteriorations; pyknosis, karyorrhexis and karyolysis. Congestion of blood vessels was indicated by the dilation of central vein. The markedly dilated central veins possessed thickening of their endothelial lining. As well as the portal areas were invaded by inflammatory lymphocytes. The present results are in agreement with the findings of Bogdan et al. (2011), Mondelli et al. (2013) and Andrezza et al. (2015) who reported cases of hepatic adverse effects and hepatocellular alterations due to interrelations in the liver of the rats treated with certain antipsychotic drugs. In the same line, Andrezza *et al.* (2015) reported that haloperidol and clozapine may induce oxidative stress in brain and liver, respectively, consistent with the documented adverse effects of these agents. In the present investigation, vascular congestion and hemorrhage were the first inflammatory histological changes observed in the liver tissue of the treated rats. These changes may be due to Haloperidol (HP) belongs to the butyrophenone group and is thought to exert its clinical effect through cerebral dopamine D₂-receptors and α -receptors. Chronic use of neuroleptics is also reported to decrease the activity of antioxidant defense enzymes, superoxide dismutase (SOD) and catalase (Naidu et al., 2003). Indeed, these changes may be resulting from the disturbance in the permeability of the blood vessels due to direct toxic action of haloperidol. This explanation agrees with Sandritter et al. (1977) who reported that fibrinoid degeneration or necrosis, develops after severe acute disturbance of vascular permeability with subsequent sudden leakage of blood plasma into the vessel wall and the surrounding connective tissue. Because of these changes, the vascular tissues are either congested or destroyed.

Hanagama et al. (2009) reported cases of hepatic injury by administration of haloperidol, they noticed severe fatty liver. The treatment with haloperidol caused

periportal, lesions with dystrophic vacuolar aspect and even hepatocyte necrosis. Hepatocytes nuclei appear sometimes pyknosis, karyorrhexis, karyolysis, reaching total disappearance with necrosed hepatocytes. This result is in harmony with that of Deleve et al. (2002), Gorrell et al. (2003) and Li et al. (2005).

The present electron microscopic observations of liver cells of haloperidol-treated rats showed that the cytoplasm of the hepatocytes showed conspicuous degeneration and vacuolation. The mitochondria underwent swelling with condensation of their matrices and some of them lost their cristae, fragmentation of rough endoplasmic reticulum into smaller stacks was also observed in the hepatocytes of this group. There was hypertrophy of Kupffer cells. The nucleus appeared with an irregular nuclear envelope and nucleoplasm showed clumps of heterochromatin adherent to the nuclear envelope. These results are in agreement with those of Halici et al. (2009) who reported severe ultrastructural changes in the liver cells of rat treated with haloperidol. The authors added that the histopathological findings at both the structural and the ultrastructural level were confirmed by stereological estimations and there is a relationship between haloperidol dose and toxic effects on the liver, and they indicated that a high dose of haloperidol may result in irreversible liver damage.

The recent successes of nanoparticles therapeutics have raised the interest of academic and industry investigators in the field of nanomedicine. There is an increasing momentum in the pace of discovery, which has resulted in the development of more complex nanoparticles systems over the past decade. These include increasing numbers of nanoscale vehicles with distinct chemical, physical, and biological properties for a myriad of clinical indications (Farokhzad and Langer 2006 and Gu et al. 2007). Besides liposome and polymeric conjugates, the most common nanoparticle platforms today include polymeric nanoparticles, micelles, nanoshells, dendrimers, engineered viral nanoparticles, albumin-based nanoparticles, polysaccharide-based nanoparticles. These nanoparticles have shown therapeutic potential for almost every branch of medicine such as oncology, immunology, neurology, endocrinology, ophthalmology, pulmonary, orthopedics, and dentistry (Farokhzad and Langer 2006).

The present results showed that the histological and ultrastructure of the liver of most rats treated with haloperidol carried on nanoparticles manifested marked improvement against the damage displayed by haloperidol only. The hepatic cords were well organized and the cytoplasmic vacuolation disappeared and most nuclei exhibited normal shape. Also, at the ultrastructure level, the results of the present study revealed marked improvements in the liver of most rats treated with haloperidol carried on nanoparticles. The hepatocytes displayed restoring the state of nearly normal appearance, i.e. their cytoplasm possesses numerous mitochondria and well developed rough endoplasmic reticulum and their nuclear envelope showing

obvious notching. These results are in agreement with the findings of Zhang et al. (2008) who define the nanotechnology is the understanding and control of matter generally in 1-100 nm dimension range. The application of nanotechnology to medicine, known as nanomedicine, concerns the use of precisely engineered materials at this length scale to develop novel therapeutic and diagnostic modalities. Nanomaterials have unique physicochemical properties, such as ultra small size, large surface area to mass ratio, and high reactivity, which are different from bulk materials of some composition. These properties can be found in traditional therapeutic and diagnostic agents.

In conclusion, the present study showed that the application of nanotechnology to haloperidol delivery has already had a significant impact of many areas of medicine, and validating the ability of nanoparticles to improve the therapeutic index of this drug.

5 References

- Andreazza, A.C.; Barakauskas, V.E.; Fazeli, S.; Feresten, A.; Shao, L.; Wei, V.; Wu, CH.; Barr, A.M.; Beasley, C.L. (2015). Effects of haloperidol and clozapine administration on oxidative stress in rat brain, liver and serum. *Neurosci. Lett.*, 591:36-40.
- Bogdan, M.; Popescu, F. and Bogdan, F. (2011). Contributions to the study of morphofunctional interrelations in the liver of the rats treated with certain antipsychotic drugs. *Rom. J. Morphol. Embryol.*, 52(1 Suppl):465–469.
- Brannon-Peppas, L. and Blanchette, J.O. 2004. Nanoparticle and targeted systems for cancer therapy. *Adv. Drug Deliv. Rev.*, 56:1649–1659.
- Cohn, T.A. and Sernyak, M.J. (2006). Metabolic monitoring for patients treated with antipsychotic medications, *Can. J. Psychiatry*, 51(8):492–501.
- Davis, J.M.; Chen, N. and Glick, I.D. (2003). A meta-analysis of the efficacy of second-generation antipsychotics, *Arch Gen Psychiatry*, 60(6):553–564.
- Deleve, L.D.; Shulman, H.M.; McDonald, G.B. (2002). Toxic injury to hepatic sinusoids: sinusoidal obstruction syndrome (venoocclusive disease, *Semin. Liver Dis.*, 22(1):27–42.
- Dykstra, M. J.; Mann, P. C.; Eiwel, M. R. and Ching, S.V. (2002). Suggested standard operating procedures (SOPs) for the preparation electron microscopy samples for toxicology/pathology studies in a GLP environment. *Toxicol. Pathol.*, 30: 735-743.
- Emerich, D.F. and Thanos, C.G. (2007). Targeted nanoparticle-based drug delivery and diagnosis. *J. Drug Target*, 15:163–183.
- Farokhzad, O.C. and Langer, R. (2006). Nanomedicine: developing smarter therapeutic and diagnostic modalities. *Adv. Drug, Deliv, Rev.* 58(14):1456-1459.
- Frei, E.; Kuchenmeister, F.; Gliniorz, R.; Breuer, A. and Schmezer, P. (2001). N-nitrosodimethylamine is activated in microsomes from hepatocytes to reactive metabolites which damage DNA of non-parenchymal cells in rat liver. *Toxicol. Lett.*, 123 (2-3): 227-234.
- Freitas, R.A. J.r. (2005). "What is Nanomedicine?" (PDF). *Nanomedicine: Nanotechnology, Biology and Medicine* 1 (1): 2–9.
- Correll, M.D.; Wang, X.M.; Levy, M.T.; Kable, E.; Marinos, G.; Cox, G.; McCaughan, G.W. (2003). Intrahepatic expression of collagen and fibroblast activation protein (FAP) in hepatitis C virus infection, *Adv. Exp. Med. Biol.*, 524:235–243.
- Groneberg, D.A., Giersig, M., Welte, T. and Pison, U. (2006). Nanoparticle-based diagnosis and therapy. *Curr. Drug Targets*, 7: 643–648.
- Gu, F.X. (2007). design considerations for cancer therapy. *Nano Today* (2): 14-21.
- Halici, Z.; Dursun, H.; Keles, O.N.; Odaci, E.; Suleyman, H.; Aydin, N.; Cadirci, E.; Kalkan, Y. and Unal, B. (2009). Effect of chronic treatment of haloperidol on the rat liver: a stereological and histopathological study. *Naunyn Schmiedebergs, Arch Pharmacol.*, 379(3):253-261.
- Hanagama, M.; Inoue, H.; Kamiya, M.; Shinone, K. and Nata, M. (2009). Gene expression on liver toxicity induced by administration of haloperidol in rats with severe fatty liver. *Leg. Med. (Tokyo)*, 10 (4):177-184.
- Ibrahim, H. M.; Ali, E.H.A. and Sabry, H. A. (2017). Haloperidol-loaded chitosan nanocomposites improve liver and kidney functions and lipid profile of male rats. (in press).
- Kawasaki, E.S. and Player, A. (2005). Nanotechnology, nanomedicine, and the development of new, effective therapies for cancer. *Nanomedicine* 1, 101–109.
- Leuchts, S.; Corves, C.; Arbter, D.; Engel, R.R.; Li, C. and Davis, J.M. (2009). Second-generation versus first-generation antipsychotic drugs for schizophrenia: a meta-analysis, *Lancet*, 373(9657):31–41.
- Li, J.; Niu J.Z.; Wang, J.F.; Li, Y.; Tao, X.H. (2005). Pathological mechanisms of alcohol-induced hepatic portal hypertension in early stage fibrosis rat model, *World J. Gastroenterol.*, 11(41):6483–6488.
- Lieberman, J.A.; Stroup, T.S.; Mcevoy, J.P.; Swartz, M.S.; Rosenheck, R.A.; Perkins, D.O.; Keefe, R.S.E.; Davis, S.M. and Davis, C.E. (2005). Clinical Antipsychotic Trials OF Intervention Effectiveness (CATIE) Investigators, Effectiveness of antipsychotics drugs in patients with chronic schizophrenia, *N. Engl. J. Med.*, 353(12):1209–1223.
- Mondelli, V.; Anacker, C.; Vernon, A. C.; Cattaneo, A.; Natesan, S.; Modo, M.; Dazzan, P.; Kapur, S.; and Pariante, C. M. (2013). Haloperidol and olanzapine mediate metabolic abnormalities through different molecular pathways. *Translational Psychiatry*, (3) e208.
- Naidu, P.S.; Singh, A. and Kulkarni, S.K. (2003). Quercetin, a Bioflavonoid, Attenuates Haloperidol-Induced Orofacial Dyskinesia. *Neuropharmacology*, 44: 1100-1106.
- Olofinjana, B. and Taylord, D. (2005). Antipsychotic drugs – information and choice: a patient survey, *Psychiatr Bull*, 29(10):369–371.

- Paget, G.E. and Barnes, J.M. (1964). Toxicity tests. In: Evaluation of Drug Activities: Pharmacometrics. Laurence, D.R. and Bacharach, A.L. (eds), Academic Press, London and New York, Pp 135-166.
- Reynolds, E.S. (1963). The use of lead citrate at high pH as an electron opaque stain in electron microscopy. *J. Cell. Biol.*, 17: 208-212.
- Robert, A. and Freitas, J.r. (1999). *Nanomedicine, Volume I: Basic Capabilities*, ISBN 1-57059-645-X .
- Sandritter, W.; Thomas,C.; Bohm, N. and Freudenberg, N. (1977). *Colour Atlas of histopathology*. Year Medical Pub. INC. Chicago, London.
- Smith, M.; Hopkins, D.; Peveler, R.C.; Holt, R.I.G.; Woodward, M. and Ismail, K. (2008). First- versus second-generation antipsychotics and risk for diabetes in schizophrenia: systematic review and meta-analysis, *Br. J. Psychiatry*, 192(6):406–411.
- Wagner, V.; Dullaart, A.; Bock, A.K.and Zweck, A. (2006). *The emerging nanomedicine landscape*. *Nat. Biotechnol.* 24 (10): 1211–1217.
- Yamazaki, K. and LaRusso, N.F. (1989). The liver and intracellular digestion: how liver cells eat! *Hepatology*, 10(5):877-86.
- Zhang, L.; Gu, F.X. ;Chan, J.M . ; Wang, A.Z. ; Langer, R.S. and Farokhzad, O.C. (2008). *Nanoparticles in Medicine: Therapeutic Applications and Developments*. *Clinical pharmacology & therapeutics* (83) 761-769