



Journal of Bioscience and Applied Research

JBAAR

WWW.JBAAR.ORG



## Biochemical and histological studies on the possible protective impact of the herb basil (*Ocimum basilicum*) on adriamycin induced toxicity in rats. I. Influence on the liver.

Bayomy\* M.F.F., Sakr, S.A., Gendia S.E. M.

Zoology Department & Faculty of Science Menoufia University, Shebin El-Kom, Egypt

(\* Corresponding author e mail. mffbayomy@yahoo.com)

### Abstract

The purpose of this work was to evaluate the effect of basil (*Ocimum basilicum*) against hepatotoxicity induced in albino rats by the anticancer drug adriamycin (ADR). The biochemical results showed that adriamycin caused significant elevation in serum ALT (Alanine aminotransferase) and AST (Aspartate aminotransferase) enzymes after 4, 6 and 8 weeks of treatment. It also caused an increase in malondialdehyde (lipid peroxidation marker) and decrease in activities of the antioxidant enzymes, superoxide dismutase and catalase. This drug has resulted in various histological changes in the liver. These changes include impairment of the normal structural organization of the hepatic lobules, congestion and dilatation of blood vessels, cytoplasmic vacuolization of the hepatocytes, leucocytic infiltrations and fatty infiltration. Treating animals with ADR and basil (*Ocimum basilicum*) led to an improvement in both biochemical and histological changes induced by ADR. There are significant decreases in ALT and AST activity. Moreover, *Ocimum basilicum* reduced the level of malondialdehyde and increased the activity of superoxide dismutase and catalase. In conclusion the results of the present work indicated that *Ocimum basilicum* had a protective effect against liver damage induced by adriamycin and this is due to antioxidant activities of some substances found in water extract of *Ocimum basilicum*.

**Keywords:** basil, adriamycin, liver, aminotransferases, antioxidant enzyme, histology.

### 1 Introduction

Adriamycin (Doxorubicin) is a drug used in the treatment course of cancer (Rizk et al., 2014). It is obtained from a bacterial species (*Streptomyces peucetius*) and it

was introduced in 1969 for tumour treatment. It is an anthracycline antitumor antibiotic and has a highly effective role in many human tumours including certain types of bladder, lung, breast, ovarian and stomach cancer (Ogawa, 1985), Hodgkin's lymphoma (Hodgkin's disease), non-Hodgkin's lymphoma and acute leukemia (Blum and Carter, 1974). Its use is limited due to the development of hepatotoxicity, nephrotoxicity and cardiotoxicity (Tallaj et al., 2005). Hepatotoxicity is one of the main side effects associated with ADR treatment. Extensive investigations have been conducted on the hepatotoxicity as well as general organ toxicity of adriamycin (Deepa and Varalakshmi, 2003; El-Sayyad et al., 2009).

Human beings have probably used medicinal plants for thousands of years for cure of their various ailments and still continue to do so (Hill, 1989). These natural products have many biologic and pharmacologic properties (Hosseinimehr, 2014). Today, it is estimated that about 80% of the world population relies on botanical preparations as medicine to meet their health needs (Ogbera et al., 2010). Basil or sweet basil (*Ocimum basilicum*) is an important medicinal plant and a culinary herb widely cultivated in many countries that contains several antioxidants compounds and considered as a major volatile oil crop (Grayer et al., 1996). This plant is belonging to the family Lamiaceae (Ghosh, 1995). It is widely used in folk medicine to treat a wide range of diseases due to its numerous pharmacological activities. Many studies have reported that basil leaf extracts have potent antioxidant, anti-aging, anticancer, antiviral, and antimicrobial properties (Akujobi et al., 2004; Chiang et al., 2005; Bozin et al., 2006; Manosroi et al., 2006; Almeida et al., 2007). The present study was conducted to reveal the influence of *Ocimum basilicum* on the hepatotoxicity of the anticancer drug, adriamycin in albino rats.

## 2 Materials and Methods

### Chemicals

Adriamycin (Doxorubicin): Doxorubicin (Adriablastina produced by Carlo Erba) was purchased from a local pharmacy in the form of 10 mg/ampoule.

Basil extract: A fresh leaves of Basil (*Ocimum basilicum*) was collected from the garden in Faculty of Science - Menoufia University, Shebin El- Kom, Egypt. The leaves were rinsed with clean water to remove any foreign matter. Leaves were blended with distilled water. The mixture was strained, the marc pressed and the mixture was filtrated using filter paper. The aqueous extract was used at a dose level of 20 ml/kg *Ocimum basilicum* (Offiah and Chikwendu, 1999).

### Animals and treatments

Healthy adult male albino rats (*Rattus norvegicus*) weighing  $120 \pm 5$  g were used. They were obtained from the breeding center of experimental animals, Helwan, Egypt. Animals were kept in the laboratory under constant temperature ( $24 \pm 2^\circ\text{C}$ ) for at least one week before and throughout the experimental work. They were maintained on a standard diet composed of 55% corn starch, 20% casein, 15% corn oil, 5% salt mixture and 5% vitaminized starch (Egyptian Company of Oils and Soap Kafr-El Zayat, Egypt). Water was available *ad libitum*. All the experiments were done in compliance with the guide for the care and use of laboratory animals (National Research Council, 1985).

Animals were divided into 4 groups:

Group 1: These animals (20 rats) were served as normal controls

Group 2: These animals (20 rats) were treated with oral aqueous *O. basilicum* extract at a dose level of 20 mg/kg for 5 days/wk through 8 weeks.

Group 3: Animals of this group (20 rats) were injected intraperitoneally with ADR at a dose level of 2 mg/kg body weight in sterile saline, once per week for 8 weeks

Group 4: Animals of this group (20 rats) treated with ADR at the same dose level as those of group 3 followed by oral administration aqueous *O. basilicum* extract at a dose level of 20 mg/kg for 5 days/wk through 8 weeks.

### Biochemical assays

For biochemical assays blood was collected and centrifuged at 3000 rpm for 10 minutes and stored at  $-20^\circ\text{C}$ . Liver function enzymes, ALT and AST, were determined in serum according to the method of Gella *et al.* (1985). malondialdehyde was determined by the method of Ohkawa *et al.* (1979) and superoxide dismutase was assayed using the method of Rest and Spitznagel (1977). Catalase activity in the sera was determined according to the method of Aebi *et al.* (1974).

### Histological preparations

Immediately after decapitation, the animals were dissected, their livers were removed from treated and control animal groups and fixed in 10% formalin. After fixation, the specimens were dehydrated using an ascending series of alcohol, cleared in 2 changes of xylene, and

embedded in molten paraffin (melting point:  $50-58^\circ\text{C}$ ). Sections of 5 mm thickness were cut using rotary microtome and mounted on clean slides. For histopathological examination, the sections were stained with Ehrlich hematoxylin and counter stained with eosin.

### Statistical analysis

The data were expressed as mean  $\pm$  standard error. Data were analyzed using Student's *t*-test and homogeneity of variances (Levene test) using statistical program of social science (SPSS) software for windows.  $P < 0.05$ ,  $P < 0.01$  and  $P < 0.001$  values were used.

## 3 Results

### Change in total body weight

Data in (Fig. 1) showed that treating animals with ADR for 8 weeks caused significant decrease in body weight of rats compared with control group. On the other hand, administration of *O. basilicum* and ADR caused significant increase in body weight of rats compared with ADR group. When *O. basilicum* was given to animals, insignificant change in body weight was recorded.

### Biochemical results

Treatment with ADR for 8 weeks caused a highly significant elevation ( $P < 0.001$ ) in the activity of ALT and AST as compared to those of the control animals. On the other hand, treatment with ADR and *O. basilicum* extract showed a reduction in the activity of these two enzymes (Figs. 2, 3). Both control and animals given *O. basilicum* showed no significant differences in serum activity of ALT and AST. Lipid peroxidation marker (MDA) increased significantly in ADR-treated animals when compared to the control group. Animals treated with ADR and *O. basilicum* showed a significant decrease in MDA when compared with ADR group (Fig. 4). Data expressed in (Fig. 5) and (Fig. 6) show that there are no significant differences in levels of SOD and CAT in both control and *O. basilicum* extract groups. Animals treated with ADR revealed that levels of SOD and CAT decreased significantly ( $P < 0.001$ ) after 4, 6 and 8 weeks of treatment. On the other hand, treating animals with ADR and *O. basilicum* extract led to an increase in these antioxidant enzymes. This increase was highly significant ( $P < 0.001$ ) after 8 weeks of treatments.

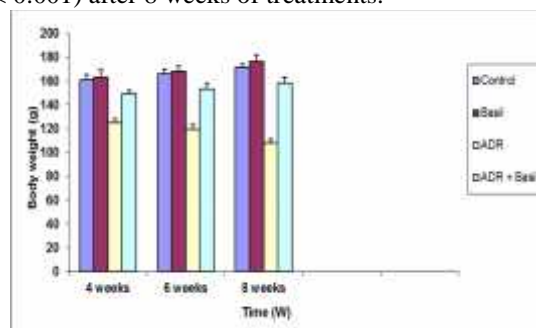


Fig. 1: Effect of Adriamycin and/or basil on body weights of rats.

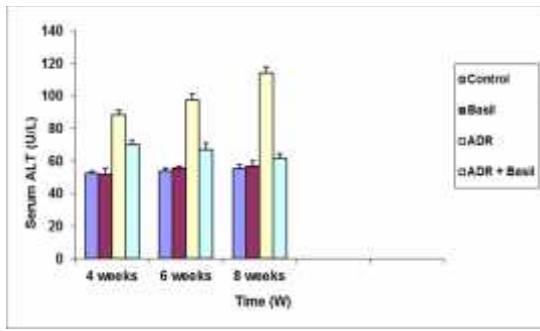


Fig. 2: Effect of Adriamycin and/or basil on serum ALT.

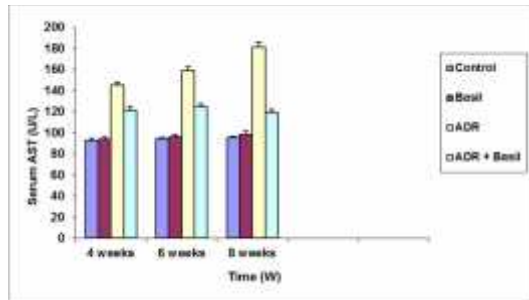


Fig. 3: Effect of Adriamycin and/or basil on serum AST.

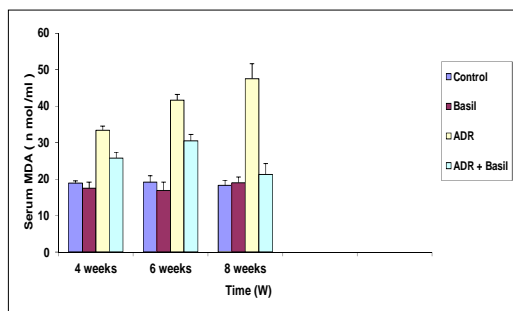


Fig. 4: Effect of Adriamycin and/or basil on serum MDA

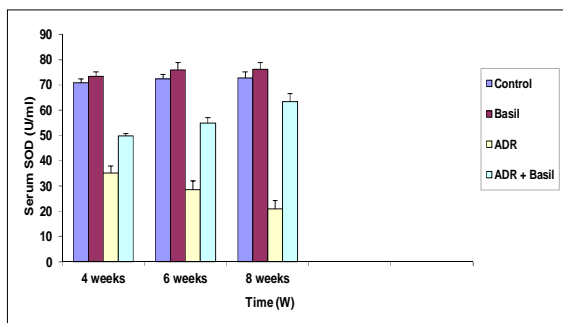


Fig. 5: Effect of Adriamycin and/or basil on serum SOD

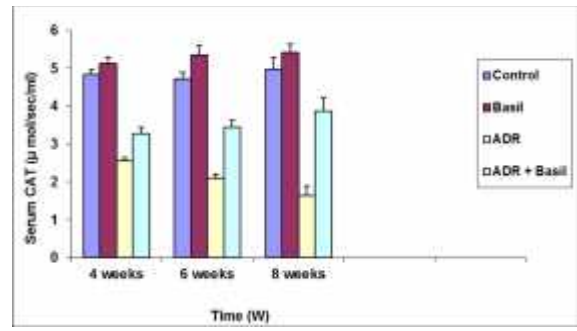


Fig. 6: Effect of Adriamycin and/or basil on serum CAT

### Histological results

Liver of control rat showed normal lobular architecture. The hepatic cells were found arranged in strands around the central vein and sinusoids appeared containing Kupffer cells (Fig. 7). Liver obtained from rats treated with basil extract exhibited the normal structure (Fig. 8). Whereas animals treated with ADR for 4 weeks revealed that the hepatic tissue was injured and the hepatic blood vessels were enlarged and congested (Fig. 9). After 6 weeks, the hepatic tissue lost its normal organization and Most of the hepatocytes showed cytoplasmic vacuolation with pyknotic nuclei (Fig. 10). After 8 weeks of treatment, these changes became intensive. The hepatic architecture was lost, clearly fatty infiltrations and masses of leukocytic infiltration were observed (Fig. 11, 12). After treatment with both ADR and *O. basilicum*, an improvement was recorded in the hepatic tissue. In these specimens, the hepatocytes appeared normal with an increase of binucleated cells (Fig. 13).

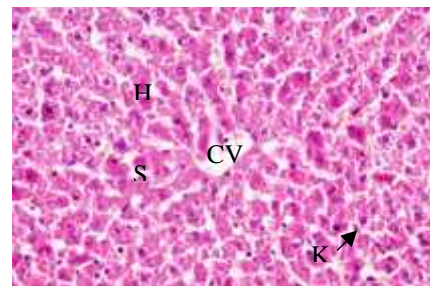


Fig. 7: Section in the liver of a control rat showing the basic structure: central vein (CV), hepatocytes (H), blood sinusoids (S) and Kupffer cells (K) (X400).

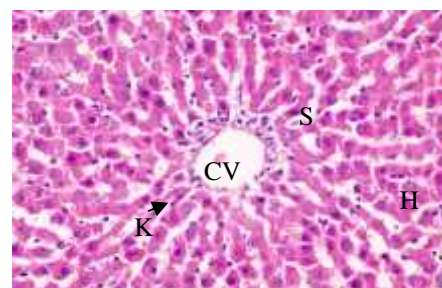


Fig. 8: Section in the liver of a rat treated with basil extract showing the hepatic architecture appeared normal, where the hepatic cells (H) arranged around central vein (CV) in



cords, Blood sinusoids (S) and Kupffer cells (K) were also observed (X400).

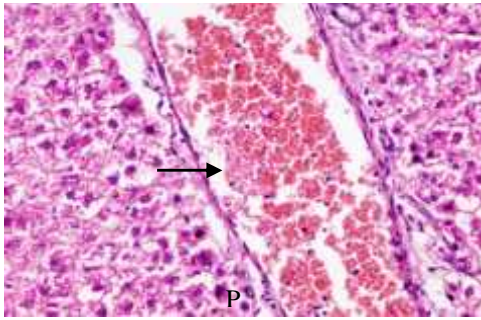


Fig. 9: Section in the liver of a rat treated with adriamycin for 4 weeks showing congested and dilated blood vessel (arrow), disruption in hepatocytes architecture with pyknotic nuclei (P) (X400).

(PV), enlarged and proliferated bile ductule (BD) and leucocytic infiltration (Li)

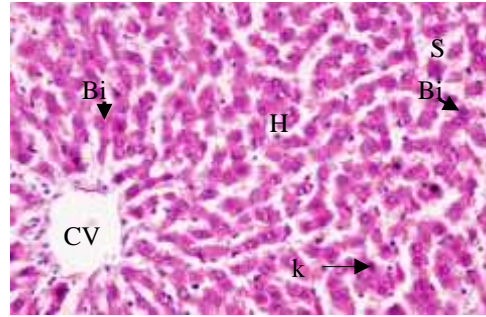


Fig. 13: Section in the liver of a rat treated with ADR and *O. basilicum* showing advanced degree of improvement, restoration of structure of the liver tissue and binucleated cell (Bi) is observed (X400).

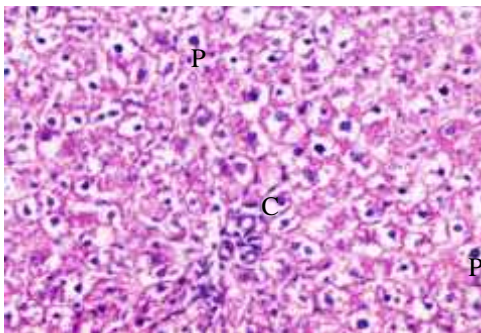


Fig. 10: Section in the liver of a rat treated with adriamycin for 6 weeks showing loss of the characteristic hepatic architecture, cytoplasmic vacuolation of the hepatocytes (C) and pyknotic nuclei (P) (X400).

#### 4 Discussion

Adriamycin is a very important agent in the treatment of cancer patients although its use may be complicated by the presence of acute and chronic side effects. It has been shown that free radicals are involved in adriamycin - induced toxicities (Yagmurca *et al.*, 2004). It has been reported that adriamycin caused severe damage in some organs like liver, testes, heart and kidneys (Shivakumar *et al.*, 2012). Adriamycin was found to cause the generation of free radicals and the induction of oxidative stress that correlates with cellular injury (Saad *et al.*, 2001). The present results revealed that ADR exerted deleterious action on the liver of rats both biochemically and histologically. Among the most sensitive and widely used liver enzymes are the aminotransferases. They include alanine aminotransferase (ALT) and aspartate aminotransferase (AST). These enzymes are normally predominantly contained within liver cells and to a lesser degree in the muscle cells. If the liver is injured or damaged, the liver cells spill these enzymes into the blood, raising the AST and ALT enzyme blood levels and signaling liver disease. Adriamycin was found to affect serum transaminases (ALT, AST). Significant increase in ALT and AST levels of sera of ADR treated rats was recorded in the present study. In agreement with this result Roomi *et al.* (2014) found that administration of ADR to old male BALB/c mice resulted in a marked increase of hepatic ALT and AST. Several investigators also obtained similar results. In this concern, Ito *et al.* (2001) observed increase in the levels of ALT and AST in the serum of adriamycin administered rats. Similarly, Guo *et al.* (2016) reported that administration of ADR at dose of 20 mg/kg increases the levels of ALT and AST. Swamy *et al.* (2011) proved that administration of ADR for two weeks elevated the activity of serum marker enzymes ALT and AST. A high lipid peroxidation with a decrease in the antioxidant enzymes, superoxide dismutase (SOD) and catalase (CAT) were recorded in liver of adriamycin-treated rats. Similarly, Swamy *et al.* (2012) observed that administration of ADR increased the MDA levels and decreased SOD and CAT

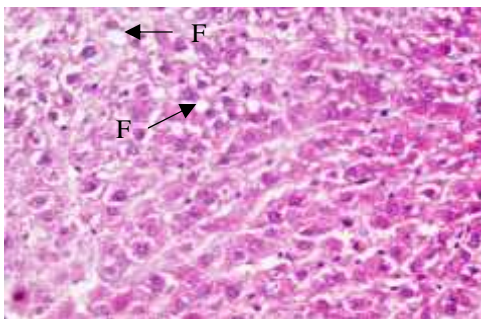


Fig. 11: Section in the liver of a rat treated with adriamycin for 8 weeks showing loss of the characteristic hepatic architecture and fatty infiltration (F). (X400).

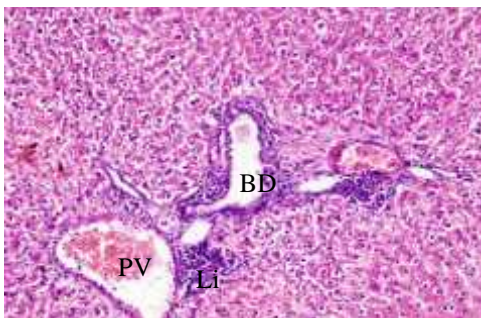


Fig. 12: Section in the liver of a rat treated with adriamycin for 8 weeks showing congested and enlarged portal vein

levels compared to the level of the normal group. Also, a study investigated that male Wister rats given a single i.p (intraperitoneal) injection of 15mg/kg/body weight of ADR caused increased the MDA levels and decreased SOD and CAT levels (Al-Sowayan and Mahmoud, 2014). Koti et al. (2009) recorded an increase in the levels of MDA and decrease in the levels of SOD and CAT after administration ADR. Many histological alterations were observed in liver of ADR treated rats. The most marked signs of tissue impairment were congestion of blood vessels, leucocytic infiltrations, cytoplasmic vaculation of the hepatocytes and fatty infiltrations. In agreement with these results, Gokcimen et al. (2007) reported that ADR increased mononuclear cells infiltration, congestion of blood vessels and necrosis. Marked changes in liver of male albino rats such as congestion of blood vessels, leucocytic infiltrations and fatty infiltration after treatment with ADR was observed by Sakr and Abo-El-Yazid (2012). Abbas (2011) noticed changes in hepatic tissue including inflammatory cell infiltration, necrosis and vacuolation after ADR administration. Also, Taher et al. (2013) revealed that higher doses of ADR caused massive hepatotoxicity including dissolution of the hepatic cords, focal inflammation, apoptosis and necrosis of the hepatic tissues with fibrosis around the portal area. Lower doses exhibited abnormal changes including vacuolation of the hepatocytes with widening of the sinusoidal capillaries in addition to congestion and vasodilatation of the central veins.

The present findings demonstrated that *O.basilicum* improves the biochemical and histological changes induced in the liver by ADR. This indicated the effectiveness of *O.basilicum* in prevention of ADR hepatotoxicity. In agreement with these observations the hepatoprotective effects of *O.basilicum* have been shown in many studies on experimental liver damage. Yamamoto *et al.* (2005) proved that *O.basilicum* suppressed hepatic fibrosis and protected liver against parenchymal damage induced by CCl<sub>4</sub>. The aqueous extract of *Ocimum americanum* leaves at doses of 200 and 400 mg /kg p.o. has significant hepatoprotective ability against paracetamol – induced hepatic damage in rats. The levels of some serum biochemical parameters such as ALT and AST in rats intoxicated with paracetamol alone had their serum AST and ALT levels significantly increased (Bayomy and Salah Eldin, 2015). The pretreatment of rats with aqueous extract of *O. americanum* leaves caused a significant decrease in the serum levels of ALT and AST (Aluko *et al.*, 2013). Oral doses of basil extract of 200 mg/k g b.w. significantly decreased the higher levels of serum of ALT and AST induced by CCl<sub>4</sub> (Yacout *et al.*, 2012). Lahon and Das (2011) reported that *O. sanctum* have hepatoprotective effect against paracetamol toxicity in rats. The hepatoprotective effects of *O.basilicum* have been shown in studies on experimental liver damage. Sakr *et al.* (2011) reported that treating animals with CCl<sub>4</sub> and aqueous leaf extracts of *O. basilica* led to an improvement, in both histopathological and biochemical alterations induced by CCl<sub>4</sub>. A study by Arhoghro *et al.* (2012) indicated that aqueous leaf extracts of *O. gratissimum* has anti-hepatotoxic action against

cisplatin induced hepatic toxicity in rats. The ameliorating effect was further evident through marked decrease in the activities of the marker enzymes ALT and AST and decreased histopathological alterations of liver tissues. Mahboub and Arisha (2015) showed that treating rats with diazinon and *O. basilicum* extract improved the histological structure of the liver and caused significant decrease of ALT and AST. These results suggested that *O. basilicum* protects the hepatocytes from injuries and improves liver function. Rasekh *et al.* (2012) decided the safety of *Ocimum basilicum* administration and found that microscopic examination of liver in control and treated animals with *O. basilicum* showed no toxic effects on this organ and supported safety of *O. basilicum* data was inferred from biochemical parameters. Chinnasamy *et al.*, (2007) reported that the protective action of ocimum was attributed to its antioxidant action. They added that this protection may be also due to the anti-inflammatory property of ocimum which reduces formation, release, and activity of inflammatory mediators such as cytokines, histamine, prostaglandins, and leukotrienes. Ocimum treatment was found to exhibit hepatoprotective effect as recorded by enhanced activity of the antioxidant enzyme, SOD and CAT and diminished amount of lipid peroxidation against the adriamycin-induced hepatotoxicity in rats. These results are in agreement with other studies which proved the antioxidant effects of *O. basilicum* extract. Sakr and Abdel samie (2015) reported that lipid peroxidation marker, MDA, was increased while the antioxidant enzymes namely SOD and CAT were decreased after Diazinon treatment. Treating animals with diazinon and *O. basilicum* extract caused a reduction of MDA level and elevation of both SOD and CAT activity. Kath and Gupta (2006) showed that hydroalcoholic extract of *ocimum sanctum* leaves lowered levels of MDA and increased levels of SOD in animal models of peptic ulcer. Ramesh and Satakopan (2010) reported that administration of *Ocimum sanctum* extract before and after cadmium intoxication resulted in a significant decrease in lipid peroxidation (LPO) levels and significant increase in SOD and CAT levels. Therefore, the results of the present work indicate that *O. basilicum* has protective effect against hepatotoxicity induced by adriamycin and this is may be attributed to its antioxidant activities of some substances found in water extract of *Ocimum basilicum*.

## 5 References

- Abbas, E.K. (2011):Histopathological changes caused by doxorubicin in laboratory mice (*Mus Musculus L*). J Pak Med Assoc. 61(11):1108-10.
- Aebi, H.; Wyss, S.R.; Scherz, B. and Skvaril, F. (1974):Heterogeneity of erythrocyte catalase II. Isolation and characterization of normal and variant erythrocyte catalase and their subunit. Enzyme, 17: 307-318.
- Akujobi, C.O.; Anyanwu, B.N.; Onyeze, G.O. and Ibekwe, V.I. (2004):Antibacterial activities and preliminary phytochemical screening of four medicinal plants. J.Appl. Sci., 7(3): 4328-4338.

- Al-Sowayan, N. and Mahmoud, N.H. (2014): The Protective Effect of Grape Seed Extract on Cardiotoxicity Induced by Doxorubicin Drug in Male Rats. *Advances in Bioscience and Biotechnology*, 5(12):1078-1089.
- Almeida, I.; Alviano, D.S., Vieira, D.P. (2007): Antigiardial activity of *Ocimum basilicum* essential oil. *Parasitol. Res.*, 101 (2): 443-452.
- Aluko, B. T.; Oloyede, O. I. and Afolayan, A. J. (2013): Hepatoprotective activity of *Ocimum americanum* L leaves against paracetamol – induced liver damage in rats,. *American Journal of Life Sciences*, 1(2): 37-42.
- Arhoghro, E. M.; Ikeh, C.; Uwakwe, A. A.; Ekpo, K. E. and Anosike, E. O. (2012): Curative potential of Aqueous extract of scent leaf (*Ocimum gratissimum*) on cisplatin induced hepatotoxicity in albino wister rats. *Journal of Pharmaceutical and Scientific Innovation*, 1(4):1-8.
- Bayomy, M.F.F and Salah Eldin, A.A. (2015): Ameliorative influence of ginko biloba extract on acetaminophen-induced oxidative stress in livers and kidneys of male albino rats. *J Bio Sci. Appl. Res.*, 1:91-96.
- Blum, R.H. and Carter, S.K.(1974): Adriamycin. A new anticancer drug with significant clinical activity. *Ann Intern Med.*80(2):249-59.
- Bozin, B.; Mimica-Dukic, N.; Simin, N. and Anackov, G. (2006): Characterization of the volatile composition of essential oils of some lamiaceae spices and the antimicrobial and antioxidant activities of the entire oils. *J. Agric. Food Chem.*, 54 (5): 1822–1828.
- Chiang, L.C.; Ng, L.T.; Cheng P.W.; Chiang W. and Lin, C.C. (2005): Antiviral activities of extracts and selected pure constituents of *Ocimum basilicum*. *Clin. Exp. Pharmacol. Physiol.*, 32(10):811-816.
- Chinnasamy, S.; Regini, G.; Kingston, C.; Kavitha, A.; Sukumaran, S. and Raj, A.(2007): Potential Anti-inflammatory Properties of CrudeAlcoholic Extract of *Ocimum basilicum* L. in Human Peripheral Blood Mononuclear Cells. *J. Of Health Science*, 53: 500-505.
- Deepa, P.R. and Varalakshmi, P. (2003): Protective effect of low molecularweight heparin on oxidative injury and cellular abnormalities inadriamycin-induced cardiac and hepatic toxicity. *Chemico. Biol.Interact.*, 146(2): 201-210.
- El-Sayyad, H.I.; Ismail, M.F.; Shalaby, F.M.; Abou-El-Magd, R.F.; Gaur, R.L.; Fernando, A.; Raj, M.H. and Ouhtit, A. (2009): Histopathological effects of cisplatin, doxorubicin and 5-fluorouracil (5-FU) on the liver of malealbino rats *Int. J. Biol. Sci.*, 5(5): 466-473
- Gella, F.J.; Olivella, T.; Cruz-Pastor, M.; Arenas, J.; Moreno, R.; Durban, R. and Gomez, J.A. (1985): A simple procedure for routine determination of aspartate aminotransferase and alanine aminotransferase with pyridoxal phosphate. *Clin. Chem. Acta.*, 153: 241-247.
- Ghosh, G.R. (1995): Tulasi (N.O. Labiatae, Genus-*Ocimum*) .*New Approaches to Medicine and Health (NAMA)*, 3:23-29
- Gokcimen, A.; Cim, A.; Tola, H.T.; Bayram, D.; Kocak, A.; Ozgüner, F. and Ayata, A. (2007): Protective effect of N-acetylcysteine, caffeic acid and vitaminE on doxorubicin hepatotoxicity. *Hum. Exp. Toxicol.*, 26(6): 519-525.
- Grayer R.; Bryan S.; Veitch N.; Goldstone F.; Paton A. and Wollenweber E. (1996):External flavones from sweet basil, *Ocimum basilicum* and related taxa. *Phytochemistry* 43, 1041 – 1047.
- Guo, H.; Liu, Y.; Wang, L.; Zhang, G.; Su, S.; Zhang, R.; Zhang, J.; Li, A.; Shang, C.; Bi, B. and Li, Z.(2016): Alleviation of doxorubicin-induced hepatorenal toxicities with sesamin via the suppression of oxidative stress. *Hum Exp Toxicol.* [Epub ahead of print]
- Hosseinimehr, S.J.( 2014): Beneficial effects of natural products on cells during ionizing radiation. *Rev. Environ. Health.*, 29(4):341-53
- Hill, A.F.(1989): *Economic Botany: A Text Book of Useful Plants and Plant Products.* 2nd Edn. New York: McGraw Hill Book Company, Inc.
- Ito, K.; Ozasa, H.; Nagashima, Y.; Hagiwara, K. and Horikawa S. (2001): Pharmacological preconditioning with doxorubicin, Implications of heme oxygenase-1 induction in doxorubicin-induced hepatic injury in rats, *Biochem Pharmacol.*, 62 : 1249.
- Kath, R.K. and Gupta, R.K.(2006): Antioxidant activity of Hydroalcoholic leaf extract of *Ocimum sanctum* in animal models of peptic ulcer. *Indian J Physiol Pharmacol.*, 50(4): 391–396.
- Koti B.C, Vishwanathswamy, A.H.; Wagawade, J. and Thippeswamy, A.H (2009): Cardioprotective effect of lipistat against doxorubicin induced myocardial toxicity in albino rats. *Indian Journal of Experimental Biology.*, 47:41-46
- Lahon, K. and Das, S. (2011): Hepatoprotective activity of *Ocimum sanctum* alcoholic leaf extract against paracetamol-induced liver damage in Albino rats. *Pharmacognosy Res.*, 3(1):13-8.
- Manosroi, J.; Dhumtanom, P. and Manosroi A.(2006): Anti-proliferative activity of essential oil extracted from Thai medicinal plants on KB and P388 cell lines. *Cancer Lett.* 235 (1): 114-120.
- Mahboub, F.A and Arisha, S.M. (2015): Hepatoprotective effect of *Ocimum basilicum* extract against the toxicity of diazinon in albino rats: Histopathological and immunohistochemical evaluation *World J Pharm Sci.*, 3(5): 790-799.
- National Research Council (1985). *Guide for use and care of laboratory animals*, Publication no. 85-23, Washington, NIH.
- Offiah, V.N. and Chikwendu, U.A. (1999): Antidiarrhoeal effects of *Ocimum gratissimum* leaf extract in experimental animals. *J Ethnopharmacol.*, 68(1-3):327-330.
- Ohkawa, H.; Ohishi, N. and Yagi, K. (1979): Assay for lipid peroxides in animals tissues by thiobarbituric acid reaction. *Anal. Boi. Chem.*, 95(2): 351-358.
- Ogawa T (1985): Studies on endoscopic local injection of an anticancer agent into experimental canine stomach cancer. *Kitakant Med. J.*, 35: 463-476.

- Ogbera, A.O.; Dada, O.; Adeyeye, F. and Jewo, P.I. (2010): Complementary and alternative medicine use in diabetes mellitus. West Afr. J. Med. 29(3): 158-162.
- Taher, M.T.; Al-Sammak, M.A. and AL-Qzazz, M.M. (2013): Effect of Doxorubicin on the Histological Structure of the Liver in Male Albino Rats. J Med J., 47 (3):220- 226.
- Tallaj, J.A.; Franco, V.; Rayburn, B.K.; Pinderski, L.; Benza, R.L.; Pamboukian, S.; Foley, B. and Bourge, R.C.(2005): Response of doxorubicin induced cardiomyopathy to the current management strategy of heart failure. J Heart Lung Transplant., 2005;24(12):2196-2201.
- Ramesh, B. and Satakopan, V. N. (2010): Antioxidant Activities of Hydroalcoholic Extract of *Ocimum sanctum* Against Cadmium Induced Toxicity in Rats. Indian J Clin Biochem., 25(3): 307–310.
- Rasekh, H.R.; Hosseinzadeh, L.; Mehri, S.; Nejad, M.K.; Aslani, M. and Tanbakoosazan, F.(2012): Safety Assessment of *Ocimum Basilicum* Hydroalcoholic Extract in Wistar Rats: Acute and Subchronic Toxicity Studies. Iran J Basic Med Sci. 15(1): 645–653.
- Rest, R.F. and Spitznagel, J.K. (1977): Subcellular distribution of superoxide dismutases in human neutrophils. Influence of myeloperoxidase on the measurement of superoxide dismutase activity. Biochem. J., 166: 145-153.
- Rizk, S.M.; Zaki, H.F. and Mina, M.A.M. (2014): Propolis Attenuates Doxorubicin-Induced Testicular Toxicity in Rats Food and Chemical Toxicology., 67: 176–186.
- Roomi, M.W.; Kalinovsky, T.; Roomi, N.W.; Rath, M. and Niedzwieck, A. (2014): Prevention of Adriamycin-induced hepatic and renal toxicity in male BALB/c mice by a nutrient mixture Exp Ther Med., 7(4): 1040–1044.
- Saad, S.Y.; Najjar, T.A. and Al-Rikabi, A.C. (2001): The preventive role of deferoxamine against acute doxorubicin-induced cardiac, renal and hepatic toxicity in rats. Pharmacol. Res., 43: 211–218.
- Sakr, S.A.; El-Abd, S.F.; Osman, M.; Kandil, A.M. and Helmy, M.S.(2011) Ameliorative Effect of Aqueous Leave Extract of *Ocimum Basilicum* on Ccl4 - Induced Hepatotoxicity and Apoptosis in Albino Rats. Journal of American Science 7(8): 116-127.
- Sakr, S.A., Abo-El-Yazid, S.M. (2012): Effect of fenugreek seed extract on adriamycin-induced hepatotoxicity and oxidative stress in albino rats. Toxicol Ind Health., 28(10):876-85.
- Sakr, S.A and Abdel Samie, H.A. (2015): Protective effect of *Ocimum basilicum* leaves extract on diazinon induced reproductive toxicity and oxidative stress in albino rats. Ejpnr., 3(1), 375-384.
- Shivakumar, P.M.; Rani, M.U.; Reddy, A.G. and Anjaneyulu, Y. (2012): A Study on the Toxic Effects of Doxorubicin on the Histology of Certain Organs Toxicol Int. 19(3): 241–244.
- Swamy, A.V.; Wangikar, U.; Koti, B.C.; Thippeswamy, A.H.; Ronad, P.M. and Manjula, D.V.(2011): Cardioprotective effect of ascorbic acid on doxorubicin-induced myocardial toxicity in rats. Indian J Pharmacol. 43(5): 507–511.
- Swamy, A.V.; Gulliaya, S. Thippeswamy, A. Koti, B.C. and Manjula, D.V.(2012): Cardioprotective effect of curcumin against doxorubicin-induced myocardial toxicity in albino rats: indian J Pharmacol., 44(1): 73-77.
- Yacout, G.A.; Elguindy, N.M and El Azab, E.F. (2012): Hepatoprotective effect of basil (*Ocimum basilicum* L.) on CCl4-induced liver fibrosis in rats African Journal of Biotechnology 11(90):15702-15711.
- Yagmurcaa, M.; Erdogan, H.; Iraz, M.; Songur, A.; Ucar, M. and Fadillioglu, E.(2004): Caffeic acid phenethyl ester as a protective agent against doxorubicin nephrotoxicity in rats. Clinica Chimica Acta, 348(1-2): 27-34.
- Yamamoto, J.; Yamada, K.; Naemura, A.; Yamashita, T. and Arai, R.(2005): Testing various herbs for antithrombotic effect. Nutrition., 21:580-587.