



Journal of Bioscience and Applied Research

JBAAR

WWW.JBAAR.ORG



Oral supplementation of aqueous *Ginkgo biloba* extract inhibits oxidative stress and hippocampus injury associated with methotrexate injection

Ehab Tousson; Ahmed Masoud; Afaf M. Elatrsh; Tamer Mostafa

Zoology Department, Faculty of Science, Tanta University, Tanta 31527, Egypt
Corresponding author e.mail. dr.tamer_ahmed_mostafa@yahoo.com

Abstract

Methotrexate is effective for the treatment of a number of cancers including breast, lung, leukemia and osteosarcoma. This study was conducted to examine the possible modifying effects of *Ginkgo biloba* against hippocampal and brain toxicity induced by methotrexate in male albino rats. This could be fulfilled through the histological, immunohistochemically and biochemical analysis of hippocampal brain tissues. The experiments were performed on 36 male albino rats divided into 6 groups; the first and second groups were the control and *Ginkgo* groups respectively while the 3rd group methotrexate rat group; the 4th and the 5th groups were co- and post treated Methotrexate rat groups with *Ginkgo* respectively and the 6th group was methotrexate self-treated rat group. In brain homogenates Malondialdehyde (MDA) levels in methotrexate group showed a significant increase when compared with control group, in contrast methotrexate-treated group also exhibited a significant decrease in brain antioxidants machinery represented by catalase, reduced glutathione (GSH) and total proteins. The histological changes consisted of destruction of oligodendrocytes, sometimes complete over large areas, and sometimes relatively slight. All the rats which survived long enough after treatment showed severe astrocytosis. Rats' brains immunocytochemical results showed that GFAP-positive cells astrocytes increase after Exposure to (MTX) compared with the other groups.

Keywords: Hippocampus, *Ginkgo biloba*, Rats, Brain, Methotrexate.

1. Introduction

Astrocytes have important functions in the development and metabolic regulation of nervous system functions (Clarke, 2013). Chemical or mechanical insults to

the brain cause transient and/or permanent changes, and astrocytes respond by a variety of reactions, including changes in cell volume, proliferation, breakdown of the energy metabolism, increased synthesis of glial fibrillary acidic protein (GFAP) and vimentin, and glial scar formation (Lindsay, 1986). Excessive production of free radicals as a consequence of ischemia/ chemical injury and traumatic damage to the brain has been implicated in the destruction of neural cells in a wide variety of acute and chronic neurologic disorders, and may underlie the alteration in brain morphology and function (Jesberger et al., 1991). The brain is specifically susceptible to chemical toxicities.

MTX is a mild immunosuppressant that also exhibits anti-inflammatory activity. It is commonly used for the treatment of certain cancers including but not limited to leukemia, Hodgkin's disease and head and neck cancers. In these illnesses, MTX is used in very large doses so that it interferes with the reproduction of the cancer cells. MTX is used in much smaller doses for the treatment of rheumatoid arthritis, Crohn's disease and psoriasis (Gottlieb 2008). The mechanisms of action of MTX are complex. Developed as a folic acid analogue, methotrexate inhibits purine and pyrimidine synthesis, which accounts for its efficacy in the therapy of cancer as well (Cronstein 2005)

Many studies have focused on the toxicities of MTX. Certain aspects of methotrexate toxicities are attributed to adenosine release (Cronstein, 2005). Exposure to (MTX) plays a critical role in neuronal death, which consequently induces apoptosis in central nervous system (CNS) neurons (Ida (Ki) Moore 2016), PC12 cells (Satoh et al., 1997; Aoshima et al., 1997), and oligodendrocytes (Richter-Landsberg et al., 1998). Although astrocytes have

a high capacity to tolerate cellular toxicity their vitality, metabolic processes and biosynthetic activities may be altered, which consequently trigger responses in neurons. Proteins, membrane lipids, nucleic acids, and components of the supporting extracellular matrix are the major targets for free radical attacks (Kasischke, 2004).

MTX toxicity might interfere with the energy metabolism by directly damaging mitochondrial structure and function. Consequently, ATP-driven transport systems and ion pumps may be impaired, including Na⁺-K⁺-ATPase, Ca²⁺-ATPase, and the Na⁺-Ca²⁺ exchanger, which plays an important role in the regulation of intracellular Ca²⁺ levels and has been identified in astrocytes (Takuma et al., 1994). This leads to a dysregulation of the control of ion and volume regulatory processes and of the osmotic balance in astrocytes, which causes astrocyte swelling, observed after traumatic stimuli by high dose of MTX and in many pathological conditions, e.g., ischemia, hypoxia, reoxygenation and toxicity (Kimmelberg 1986; Kimmelberg 1991).

Herbal products account for a substantial portion of the current interest in alternative treatments and Ginkgo biloba (GB) figures prominently in this interest. Interest in GB. However, has a long history Fossil records place its origins 150 to 250 million years ago (Charm et al., 1997). Ginkgo (derived from the Chinese Yin-Kuo, meaning "silver apricot") biloba (referring to its two-lobed, fan-shaped leaves) is derived from the leaf of the Maidenhair tree, which is believed to live 2,000 to 4,000 years (DeFeudis 1991).

Interest in the medicinal properties of GB can be traced back some 5,000 years to ancient China, where the healer Chen Nong (2767 to 2687 BC) described the medicinal properties of the plant in the first known pharmacopoeia. Called the Chen Nong Pen T'sao (Charm et al., 1997). Indications included ailments of the heart and lungs (Tousson et al., 2014) with the notation that inhaling its steam and imbibing its tea were palliative for both asthma and bronchitis (DeFeudis 1991).

While firmly rooted in antiquity, GB is today the most frequently prescribed herbal preparation in Germany (Knipschild 1992) and one of the most commonly used over-the-counter (OTC) herbal preparations in the United States (Landes 1997). In 1964, a GB extract called EGb 761 was developed by a German pharmaceutical company, and since that time hundreds of studies have examined ginkgo's effects in human and animal models. The German Commission E (Blumenthal 1998) (equivalent to the US Food and Drug Administration for botanicals) has approved GB for symptomatic treatment of deficits in memory, concentration, and depression from organic brain disease.

GB extract or one of its components has been extensively studied in terms of its effects on the cognitive, physiologic, and psychiatric sequelae associated with neurologic and vascular conditions. Specific functions and conditions include recall/ recognition memory, reaction time, attention, concentration, psychomotor function, fatigue, mood, outcomes, and information processing

speed. GB has also been used experimentally in treating impairments and symptoms in Alzheimer's and age-associated Dementia, traumatic brain injury, stroke, multi-infarct dementia, cerebral atherosclerosis, cerebral insufficiency, cerebral edema, inflammation, glutamate toxicity, necrosis, apoptosis, tinnitus, sexual dysfunction, and macular degeneration (Diamond 1999). Based on these evidences, this study was conducted to examine the possible modifying effects of GLE against hippocampal and brain toxicity induced by methotrexate in male albino rats.

2 Experimental animals & study design

2.1. Animals

The experiments were performed on 36 male albino rats Weighing 150 ± 10 g and of 9-10 week's age. They were obtained from our laboratory farms, Zoology Department, Faculty of Science, Tanta University, Tanta, Egypt. The rats were kept in the laboratory for one week before the experimental work and maintained on a standard rodent diet (20% casein, 15% corn oil, 55% corn starch, 5% salt mixture and 5% vitaminized starch; Egyptian Company of Oils and Soap Kafr-Elzayat Egypt) and water available ad libitum. The experimental protocol was approved by Local Ethics Committee and Animals Research.

2.2. Ginkgo biloba Extract (GLE) Preparation

The extraction procedure for Ginkgo biloba leaves was carried out as reported by (Sener et al., 2006)

2.3. Animal treatments

The rats were randomly and equally divided into groups (6) animals each:

G1: control group in which animals did not received any treatment;

G2: Ginkgo biloba group in which animals received orally *Ginkgo biloba* extract (300 mg/kg BW/week) for four weeks according to Tousson et al.,(2014).

G3: (methotrexate, MTX) rats group in which rats were injected intraperitoneally with MTX (0.5 mg/kg body weight/twice a week) for four weeks (Yozai et al., 2005).

G4: co-treated group in which animals injected intraperitoneally with MTX (0.5 mg/kg body weight/twice a week) and also received orally *Ginkgo biloba* group (300 mg/kg body weight/week) for four weeks;

G5: post-treated group in which animals injected intraperitoneally with MTX administration (0.5 mg/kg body weight/twice a week) for four weeks and then treated orally with *Ginkgo biloba* extract (300 mg/kg body weight/week) for another four weeks;

G6: self-treated rat group in which rats were injected intraperitoneally with MTX administration (0.5 mg/kg body weight/twice a week) for four weeks and self-treated without drugs for another four weeks.

2.4. Sample Preparation

Animals were fasted overnight for clinical examination. After animals were sacrificed, the brain was instantly removed, washed three times in ice cold saline and blotted on filter paper, then used for preparation of tissue homogenates for estimation of tissue MDA, total protein, Reduced glutathione (GSH) and catalase enzymes.

2.5. Preparation of tissue Homogenates

Tissue homogenates were prepared as reported by (Sakeran et al., 2014). Briefly, specimens were separated into two parts. Each piece was weighed and homogenized separately with a Potter Elvehjem tissue homogenizer. The crude tissue homogenate was centrifuged at 11,739 rcf, for 15 min in a cold centrifuge, and the resultant supernatant was used for the different estimations.

2.6. Enzymatic and Non-enzymatic Antioxidant Assays

Malondialdehyde (MDA) in brain was detected by the method of (Mesbah et al., 2004). The catalase (CAT) activity in brain was detected by the method of (Sakeran et al., 2014). Reduced glutathione (GSH) in brain was detected by the method of (Beutler et al., 1963). The total protein concentration in brain was detected by the method of (Lowry et al., 1951) as modified by (Tsuyosh and James 1978).

2.7. Histopathological examination

Immediately after decapitation animals were dissected, brain from different groups were quickly removed and fixed in 10 % neutral buffered formalin. After fixation, specimens were dehydrated in an ascending series of alcohol, cleared in two changes of xylene and embedded in molten paraffin (mp. 50–58°C). Sections of 5 microns thickness were cut using rotary microtome and mounted on clean slides. Sections were stained with Ehrlich's haematoxylin and counterstained with eosin as a routine method after (Bancroft and Stevens 1990). All stained slides were viewed by using Olympus microscope and images were captured by a digital camera (Cannon 620).

2.8. Immunohistochemical detection of GFAP

GFAP antibody stain: Cat. # MS280R7

For expression of GFAP (clone: GA-5), formalin fixed midbrain sections were deparaffinized and rehydrated, slide incubated in Hydrogen Peroxide Block for 10-15 minutes, washed 4 times in phosphate buffer, the slides incubated for 5 minutes at room temperature with Ultra V Block to block nonspecific background staining, the sections incubated 5-15 minutes with GFAP antibody (Thermo scientific, USA) ready to use stain, the slides counterstained with Hematoxylin and coverslipped using a permanent mounting media, the prepared sections were examined by mean of a research microscope.

3 Results

1. Oxidative stress in different groups

1.1. Lipid peroxidation (MDA) levels in Brain

MDA levels in brain tissue of the studied groups are illustrated in (Figure 1) MDA level in brain tissue in MTX only group showed significant increased as compared to control and Gingko biloba groups. Also co-treatment and post treatment groups showed significant decrease as compared to MTX only group and significant increase as compared to control and *Gingko biloba* group. *Gingko biloba* group showed non-significant as compared to control group. In self treated MTX group showed significant increase compared to control and *Gingko biloba* groups, but self-treated MTX group were significantly increase when compared with co-treatment MTX group.

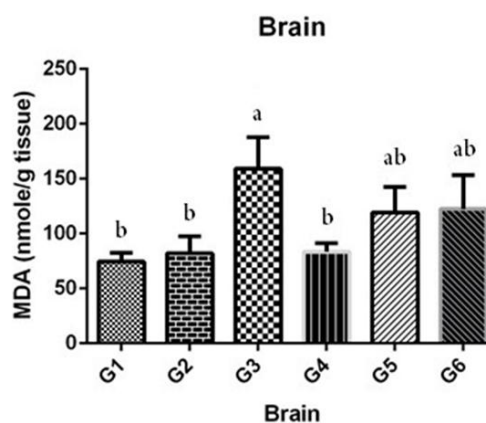


Figure 1: Changes in MDA (nmole/g tissue) levels in Brain tissue different groups under study. Where G1 Control group; G2 *Gingko biloba* group; G3 MTX group; G4 Co-treated MTX group with *Ginkgo biloba*; G5 Post-treated MTX group with *Gingko biloba*; G6 Self-treated MTX group. a Significantly different from control (G1) group. b Significantly different from MTX (G3) group.

1.2. Catalase levels

Catalase level in brain tissue of the studied groups are illustrated in (Figure 2) Catalase level in brain tissue in MTX only group showed significant decreased as compared to control and *Gingko biloba* groups. Also co-treatment and post treatment groups showed significant increase as compared to MTX only group and significant decrease as compared to control and *Gingko biloba* group. *Gingko biloba* group showed non-significant as compared to control group. In self treated MTX group showed significant decrease compared to control and *Gingko biloba* groups, but self-treated MTX group were significantly decreased when compared with co-treatment MTX group.

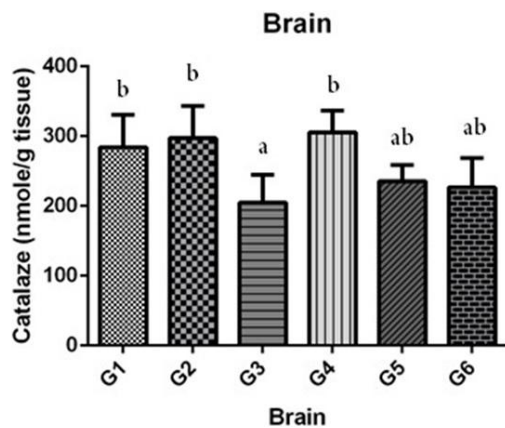


Figure 2: Changes in Catalase (nmole/g tissue) levels in Brain tissue different groups under study. Where G1 Control group; G2 *Ginkgo biloba* group; G3 MTX group; G4 Co-treated MTX group with *Ginkgo biloba*; G5 Post-treated MTX group with *Ginkgo biloba*; G6 Self-treated MTX group. a Significantly different from control (G1) group. b Significantly different from MTX (G3) group.

1.3. GSH levels in Brain

GSH level in brain tissue of the studied groups are illustrated in (Figure 3) GSH level in brain tissue in MTX only group showed significant decrease as compared to control and *Ginkgo biloba* groups. Also co-treatment and post treatment groups showed significant increase as compared to MTX only group and significant decrease as compared to control and *Ginkgo biloba* group. *Ginkgo biloba* group showed non-significant as compared to control group. In self treated MTX group showed significant decrease compared to control and *Ginkgo biloba* groups, but self-treated MTX group were significantly decreased when compared with co-treatment MTX group.

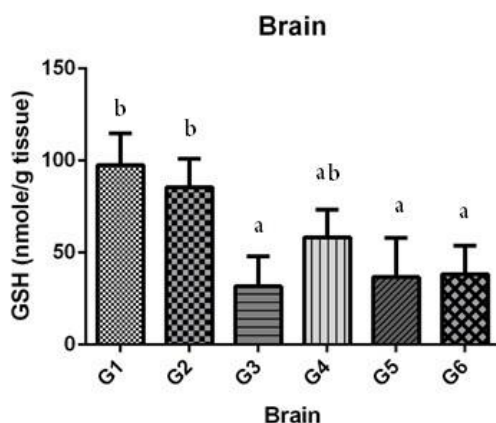


Figure 3: Changes in GSH (nmole/g tissue) levels in Brain tissue different groups under study. Where G1 Control group; G2 *Ginkgo biloba* group; G3 MTX group; G4 Co-treated MTX group with *Ginkgo biloba*; G5 Post-treated MTX group with *Ginkgo biloba*; G6 Self-treated MTX group. a Significantly different from control (G1) group. b Significantly different from MTX (G3) group.

1.4. Total protein levels in brain

Total protein level in brain tissue of the studied groups are illustrated in (Figure 4) Total protein level in brain tissue in MTX only group showed significant decrease as compared to control and *Ginkgo biloba* groups. Also co-treatment and post treatment groups showed significant increase as compared to MTX only group and significant decrease as compared to control and *Ginkgo biloba* group. *Ginkgo biloba* group showed non-significant as compared to control group. In self treated MTX group showed significant decrease compared to control and *Ginkgo biloba* groups, but self-treated MTX group were significantly decreased when compared with co-treatment MTX group.

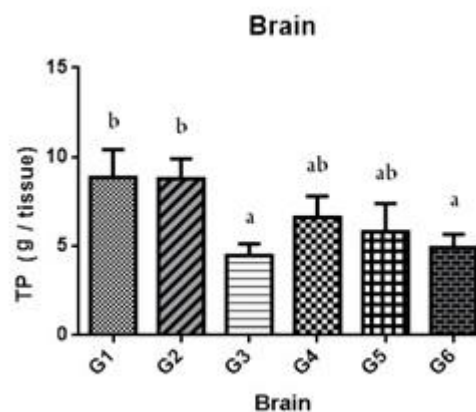


Figure 4: Changes in total protein (g/tissue) levels in brain tissue different groups under study. Where G1 Control group; G2 *Ginkgo biloba* group; G3 MTX group; G4 Co-treated MTX group with *Ginkgo biloba*; G5 Post-treated MTX group with *Ginkgo biloba*; G6 Self-treated MTX group. a Significantly different from control (G1) group. b Significantly different from MTX (G3) group.

2. Histological observations

Representative sections of H&E stain obtained from the hippocampus in different groups under study are shown at the light microscope levels in Figures (5-10). The hippocampus is a major component of the rat brains that lies beneath the cerebral cortex and it is characterized by a thin layer of densely packed pyramidal cells, enclosed by an outer plexiform layer and an inner polymorph layer. The hippocampus is divided into three main subdivisions, ie. CA1, CA2, and CA3. CA1 can be easily recognized in H&E-stained sections due to its layer of neatly aligned pyramidal cells. The CA2 and CA3 parts of the Ammon's horn are characterized by the presence of large pyramidal cells, forming a few closely-packed layers on the top of one another. No histological changes were observed in the CA1, CA2 and CA3 regions of hippocampus of control group (Fig. 5). The histopathological examination of rat brain that treated with methotrexate showed various histopathological changes, these alternations were increased with the treatment by the methotrexate (Fig. 7). This histopathological changes showed a large number of degenerating (i.e., shrunken, argyrophilic) neurons with reduction and distortion of the pyramidal cells were

observed in the hippocampus (Fig. 7) when compared with the hippocampus of control rat (Fig. 5). Hippocampus in MTX (Fig. 7) showed marked neurofibrillary degeneration damages neurons and marked neurofibrillary degeneration. Hippocampus in co-treated with GB (Fig. 8) showed mild damages neurons with clear oedema and moderate neurofibrillary degeneration damages neurons and these changes increased after long dose of methotrexate even if Post-treated with GB dose (Fig.10).

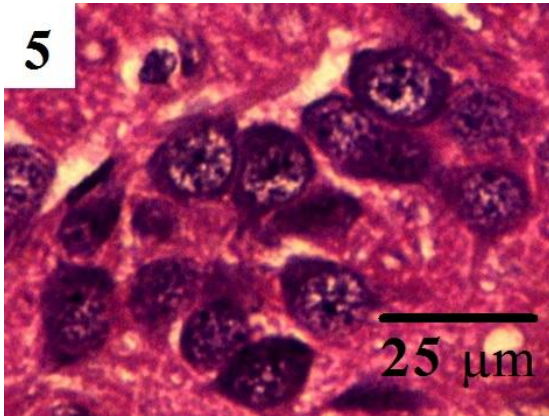


Fig. 5: Photomicrograph of a rat brain coronal section (stained by HE) in control rat showing normal structure of hippocampus.

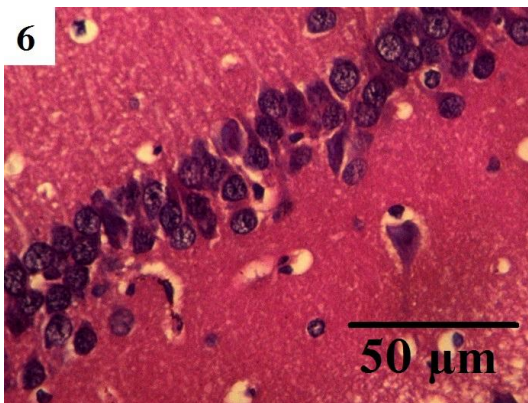


Fig. 6: Photomicrograph of rat brain coronal section (stained by HE) in GB-treated rat showing normal structure of hippocampus.

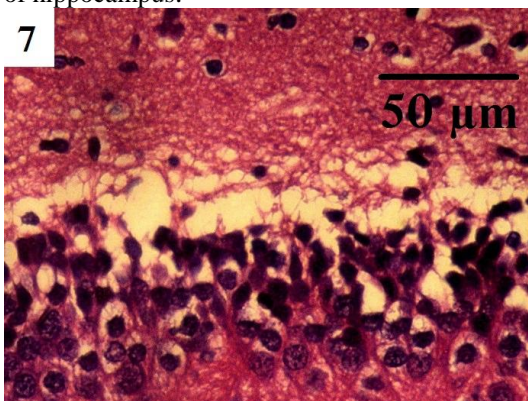


Fig. 7: Photomicrograph of a rat brain coronal sections (stained by HE) in dose Methotrexate only treated rat showing marked diffuse vacuolar degeneration and damages neurons in hippocampus.

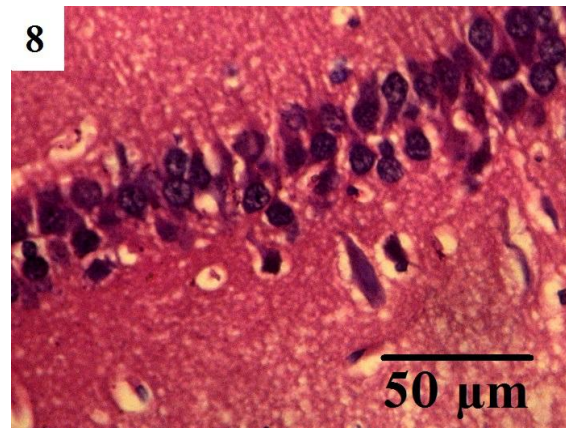


Fig. 8: Photomicrographs of rat brain coronal sections (stained by HE) in dose methotrexate treated co-GB rat showing mild damage and distortion of the pyramidal cells in hippocampus.

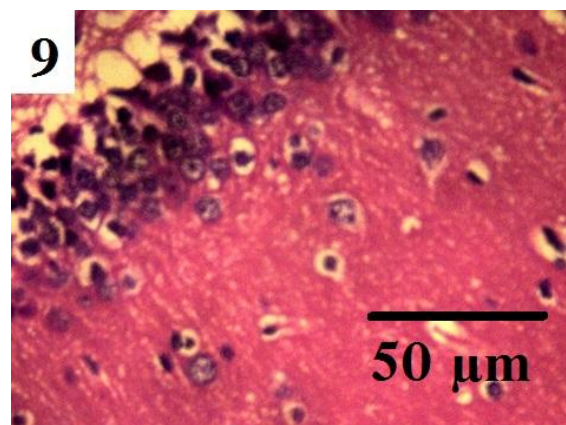


Fig. 9: Photomicrographs of rat brain coronal sections (stained by HE) in dose Methotrexate treated & post treated with GB rat showing marked damage and distortion of the pyramidal cells in hippocampus.

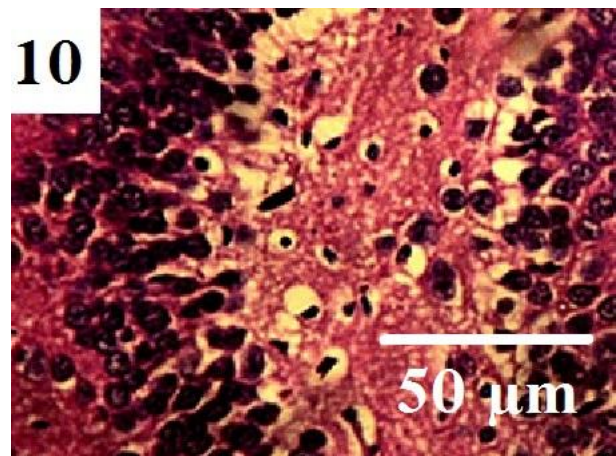


Fig. 10: Photomicrographs of rat brain coronal sections (stained by HE) in dose Methotrexate treated self-recovery rat showing marked diffuse vacuolar degeneration and damages neurons in hippocampus.

3. Immunohistochemical results

The detection and distribution of GFAP immunoreactivity in the brain sections in the different groups under study were revealed in Figs.11-16. Hippocampus microglia in control and *Gingko biloba* groups showed low positive affinity for GFAP (Figs. 11 and 12), strong positive affinity for GFAP were observed in the microglia of the hippocampus Brain sections in Methotrexate rat group (Fig. 13), moderate positive affinity for GFAP in microglial cells in co-treated *Gingko biloba* group were detected while the intensity of GFAP stain reaction were significantly increase in microglia in post- treated with *Gingko biloba* (Figs. 14 and 15), very strong positive affinity for GFAP in microglia in self-treated rat group (Fig 16).

The intensity of GFAP in microglia in methotrexate rat group was increased when compared with control rat group. The intensity of GFAP in microglia in treated rat group with methotrexate was increased when compared with co-treated and post-treated rats with *Gingko biloba* groups. The intensity of GFAP were very strong affinity in microglia in self-treated group when compared with co-treated and post-treated rats with *Gingko biloba* groups. The intensity of GFAP in microglia in self-treated rats was increased when compared to methotrexate rat brains indicating a deterioration in the health of brain cells during the time period in which the drug stopped.

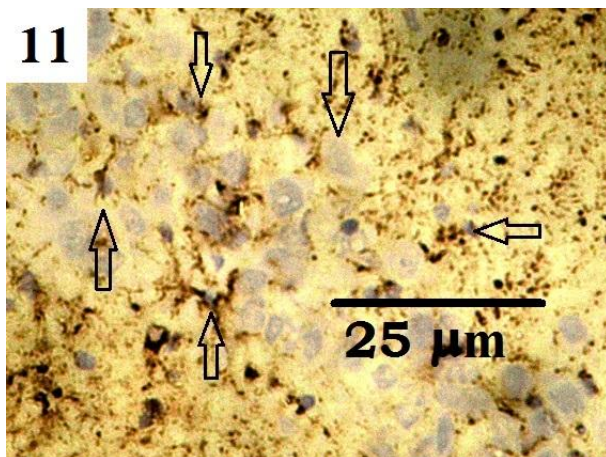


Fig.11.Rat hippocampus section in control rat showed low affinity reaction for GFAP in microglia (arrows).

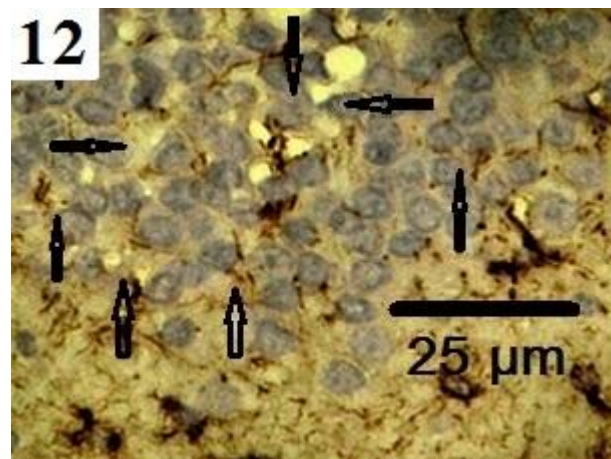


Fig.12.Rat hippocampus section in GB groups showed low affinity reaction for GFAP in microglia (arrows)




Fig.13. Rat hippocampus section in methotrexate group showed very high affinity reaction for GFAP in microglia (arrows).

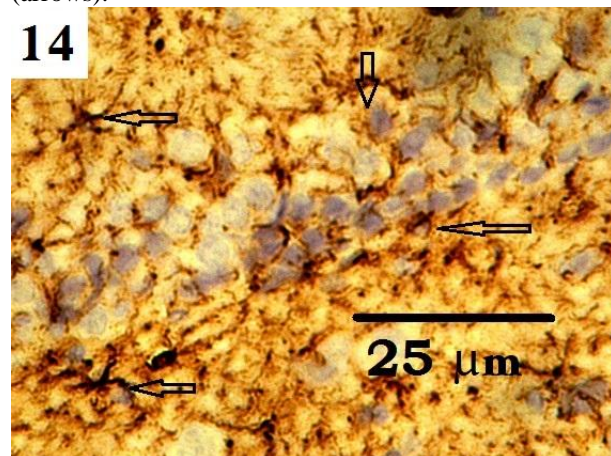


Fig.14. Rat hippocampus section in co-treated rat with *Gingko biloba* group showed moderate to high affinity reaction for GFAP in microglia (arrows).




Fig.15. Rat hippocampus section in post-treated rat with Gingko biloba group showed moderate to high affinity reaction for GFAP in microglia(arrows).




Fig.16. Self-treated group showed very high affinity reaction for GFAP in microglia(arrows).

4 Discussion

The damage in the rat brains observed in the present work was confined to the white matter of the cerebrum and cerebellum. Control and GB groups did not show this astrocytosis, The mechanism of this astrocytosis is not clear, but it does not seem to be the usual repair process resulting from tissue damage as there is only slight fibre formation. If one accepts the unitary theory of neuroglia, it could be argued that these astrocytes were originally damaged oligodendrocytes. Apart from the cases in the last 4 groups which showed post mortem manifestations, there were no cases of encephalitis, haemorrhage, or other known causes of cerebral pathology except MTX effect on astrocytes.

There have been a number of reports of brain damage after methotrexate injection into the intraperitoneal pathways (Bresnan et al., 1992; Shapiro et al., 1993; Norrell et al., 1994 Wilson et al., 1999). The drug has been given indirectly for brains, often intraventricularly and in many cases there has been obstruction in the ventricular system. The main histological changes seen were areas of

coagulative necrosis in the white matter as in group 3, in this group the damage was severe, but it was also present in the white matter of the cerebellum. Rubin et al., (1998) have shown that in dogs, tritiated methotrexate diffuses through the brain in a similar manner to inulin, and that in vitro it can enter the choroid plexus against the concentration gradient. Although the damage may be dose-dependent, it is suggested that it spreads diffusely throughout the nervous tissue even when given intraperitoneally. In fact, if it did not do so, it would be ineffective as foci of perivascular malignancy deep in the brain are often seen post mortem effects. Kay et al. (1992) described seven cases of encephalopathy after intraperitoneal methotrexate presenting mainly as confusion, dementia, and unsteadiness with EEG changes. Except co GB gp all MTX groups was examined histologically and showed lesions described as infarcts, and fibrinoid necrosis of blood vessel walls do not say whether there were fat granule cells or myelin breakdown. These lesions may be of a similar nature to those seen in the last 4 groups.

Brain damage after intraperitoneal methotrexate includes fibrinoid necrosis and it seems that methotrexate itself has a direct toxic effect on the oligodendrocyte. This cell does have a rather different metabolic make-up to the neuron which is unaffected. Toxicity is dependent largely on the pentose shunt for its energy and is low in Krebs cycle enzymes and cytochrome oxidase (Meyer and Meyer, 1994). This does not, however, explain why it should be more sensitive to folate antagonists. It is possible that methotrexate remains bound to the cell, inhibiting further nucleic acid synthesis (Berlin et al., 1993).

Intraperitoneal methotrexate may have two possible sequelae. One is severe brain damage, possibly fatal. If this occurs after a normal single course of treatment, it must be assumed that the rat has some metabolic abnormality which makes him unduly sensitive to folate deficiency. The second probably occurs in most cases and consists of patchy oligodendroglial loss with severe consecutive astrocytosis. This has no obvious clinical expression, could be considered irrelevant. However, some of children and young adults who are surviving MTX long periods in few doses and are possibly cured, therefore any brain damage is undesirable (Roger J. Packer 1987)

Astrocytes, the predominant cell type of the nervous system, have important neuroregulatory functions that include regulation of neuron communication, neurosecretion, metabolism and synaptic plasticity (Mahesh et al., 2006). In addition, astrocytes respond to chemical drugs such as MTX with a graded cellular activation in relation to severity of injury, referred to as reactive gliosis. They make essential contributions to many homeostatic functions that could directly influence neuronal survival, tissue integrity and functional outcome after MTX (Floyd and Lyeth, 2007).

In this study, higher basal expression of GFAP in hippocampus was observed in MTX-rat groups as compared to 1st two groups. Methotrexate injection increase in basal expression of GFAP and protein levels has been observed in MTX-rats (Yoshida et al., 1996). The increase

in GFAP expression has been shown to roughly parallel an increase in the number of reactive astrocytes of rats injected with MTX (Goss et al., 1991). MTX increases GFAP or protein in extracts of the whole hippocampus have been attributed to more GFAP molecules per cell (Major et al., 1997), likely due to morphological changes associated with activation. In accord with that observation, the injured hippocampus shows an altered astrocyte phenotype with hypertrophic soma and thickening of the processes. Astrocyte hyperplasia and hypertrophy has been observed in several areas of the MTX-rat brains accompanied by an elevated content of GFAP (Francesco Amenta, 1998), which is associated with a reduction in neuroprotective capacity (Pertusa et al., 2007).

Oxidative stress describes a condition in which cellular antioxidant defenses are insufficient to keep the levels of antioxidant enzymes below a toxic threshold (Rajamani et al. 2006). The current investigation has shown that 4-weeks injection of MTX leads to folate deficiency rats might result in variable oxidative stress changes in all the brain regions. Brain is more vulnerable to oxidative damage due to its high oxygen consumption and due to the presence of high levels of polyunsaturated fatty acids (Floyd and Carney, 1992). Moreover, the condition could also be associated with the abundance of redox active transition metal ions, and the relative dearth of antioxidant defense system (Samuel et al., 2005). It is well known that the nervous system is highly susceptible for chemical drugs intoxication (Wallace et al., 1997; Sadun, 1998). The GSH, catalase, TP levels has been found to be decreased while MDA levels increased in all the regions of brain studied, after MTX injection.

The present results showed that GB ameliorated MTX toxicity. Several studies tried to find out whether the neuroprotective effect of GB extract against various types of brain injury which results in an improved neurological outcome. In most cases, changes in behavior, learning and memory ability under normal conditions as well as after injury were measured by passive avoidance tests (Hoyer 1999). In MTX rats, impaired cell behavior was significantly slowed down by co-GB treatment which showed mild damages neurons with clear oedema and moderate neurofibrillary degeneration damages neuron. Moreover, GB-treatment caused a decrease of MDA and improved the antioxidant enzymes. It is concluded from this work that injection of MTX caused increased production of free radicals and GB act as antioxidant compound against toxicity of MTX.

5 References

Aoshima M, Satoh T, Sakai N, Yamada M, Enokido Y, Ikeuchi T, Hatanaka H. (1997). Generation of free radicals during lipid hydroperoxide-triggered apoptosis in PC12h cells. *Biophys Biochem Acta* 1345:35-42.

Alice G., Neil J., Kenneth B., Steven R., Mark L., John Y., Abby S., Craig A., Craig L., Karl R.; (2008). Guidelines of care for the management of psoriasis and psoriatic arthritis : Section 2. Psoriatic arthritis: Overview and guidelines of care for treatment with an emphasis on

the biologics. *Journal of the American Academy of Dermatology*. 58(5): 851–864.

Atabay C, Cagnoli CM, Kharlamov E, Ikonovic MD, Manev H. (1996). Removal of serum from primary cultures of cerebellar granule neurons induces oxidative stress and DNA fragmentation: protection with antioxidants and glutamate receptor antagonists. *J Neurosci Res* 43:465–475.

Bancroft JD, Stevens A. (1990). *Theory and Practice of Histological Technique*. 3rd Ed. Churchill Living stone. Edinburgh, London benefits in Stage +2 postmenopausal women after 6 weeks of treatment with Ginkgo biloba. *J Psychopharmacol* 1990; 19: 173-181.

Berlin, N. I. (1993). Folic acid antagonists-Effects on the cell and the patient. *Annals of Internal Medicine*, 59, 931- 956.

Beutler E, Duron O, Kelly BM.(1963). Improved method for the determination of blood glutathione. *J Lab Clin Med*; 61: 882-888.

Blumenthal M (1998). *The complete German commission E monographs: therapeutic guide to herbal medicines*. Austin (TX): American Botanical Council. 61(9): 241-365

Bonfoco E, Krainc D, Ankarcona M, Nicotera P, Lipton SA. (1995). Apoptosis and necrosis: two distinct events induced respectively by mild and intense insults with NMDA or nitric oxide/superoxide in cortical cell cultures. *Proc Natl Acad Sci USA* 92:7162–7166.

Bresnan, M. J., Gilles, F. H., Lorenzo, A. V., Watters, G. V., and Barlow, C. F. (1992). Leucoencephalopathy following combined irradiation and intraperitoneal methotrexate therapy of brain tumors in children. *Transactions of the American Neurological Association*, 97: 204-206.

Bruce J., Samuel C., Nancy F., Robert J., Olga N., Jennifer A. Richards, Nancy E., (2000). Ginkgo biloba extract: Mechanisms and clinical indications. *Sciencedirect*. 81(5): 668–678

Bruce N. Cronstein (2005).. *Pharmacological Reviews* June 2005, 57 (2) 163-172.

Charm JY, Chang MN. (1997) Medicinal uses of Ginkgo biloba. *Today's Therapeutic Trends*; 15:256-55

Clarke L., Barres B., (2013). Emerging roles of astrocytes in neural circuit development. *Nature Reviews Neuroscience*; 14, 311-321.

Cronstein BN. (2005). Low-dose methotrexate: a mainstay in the treatment of rheumatoid arthritis. *Pharmacol Rev.*; 57(2):163-72.

DeFeudis FV. (1991). Ginkgobiloba extract (EGb 761): pharmacological activities and clinical applications. *Paris: Else & R*; 25(14):135-54.

Floyd, C.L., Lyeth, B.G., (2007). Astroglia: important mediators of traumatic brain injury. *Prog. Brain Res*. 161, 61–79.

- Floyd, R.A., Carney, J.M., (1992). Free radical damage to protein and DNA: mechanism involved and relevant observation on brain undergoing oxidative stress. *Ann. Neurol.* 32 (Suppl.), S22–S27.
- Francesco Amenta, E.B.M.S.J.A.V., (1998). Astrocyte changes in aging cerebral cortex and hippocampus: a quantitative immunohistochemical study. *Microsc. Res. Tech.* 29–33.
- Goss, J.R., Finch, C.E., Morgan, D.G., (1991). Age-related changes in glial fibrillary acidic protein mRNA in the mouse brain. *Neurobiol. Aging* 12, 165–170.
- Hoyer S., Lannert H., Nöldner M. and Chatterjee S. S. (1999) Damaged neuronal energy metabolism and behavior are improved by Ginkgo biloba extract (EGb 761). *J. Neural. Transm.* 106: 1171–1188
- Ida M., Carrie J., Howard B. Adam R., Ashley M., Sara S. David W. (2016). Effects of Intraventricular Methotrexate on Neuronal Injury and Gene Expression in a Rat Model. *Biological research for nursing*; 18 (5) 505-514
- Karl A. Kasischke, Harshad D. Vishwasrao, Patricia J. Fisher, Warren R. Zipfel, Watt W. Webb; *Science* : (2004) 305 (5680): 99-103
- Kimelberg HK. (1991). Swelling and volume control in brain astroglial cells. In: Gilles R, Hoffman EK, Bolis L, editors. *Advances in comparative and environmental physiology 9: volume and osmolality control in animal cells.* Berlin, Heidelberg, Germany: Springer-Verlag. p. 81–117.
- Kimelberg HK, Ransom BR. (1986). Physiological and pathological aspects of astrocytic swelling. In: Federoff S, Vernadakis A, editors. *Astrocytes*, vol 3. Orlando: Academic Press. p. 129–166.
- Kleijnen J. Knipschild P. (1992) Ginkgo biloba. *Lancet*; 340: 1136-9.
- Knapton, P. J., O'Sullivan, J. P., Wells, D. G., Harris, R. F., Innes, E. M., Stuart, J., Schwartz, F. C. M., and Thompson, E. N. (1992). Encephalopathy in acute leukaemia associated with methotrexate therapy. *Archives of Diseases in Childhood*, 47, 344-354.
- Landes P. (1997). Market report: Whole Foods magazine's 2nd annual herb market survey for U.S. health food stores. *HerbalGram*; 40:52.
- Lindsay R. (1986). Reactive gliosis. In: Federoff S, Vernadakis A, editors. *Astrocytes: cell biology and pathology of astrocytes*, vol 3. New York: Academic Press. p. 231–262.
- Lowry OH, Rosebrough NJ, Farr AL, Randall RJ. (1951). Protein measurement with Folin phenol reagent. *J. Biol. Chem.*; 193: 265-275.
- Mahesh, V.B., Dhandapani, K.M., Brann, D.W., (2006). Role of astrocytes in reproduction and neuroprotection. *Mol. Cell Endocrinol.* 246, 1–9.
- Major, D.E., Kessler, J.P., Cotman, C.W., Finch, C.E., Day, J.R., (1997). Life-long dietary restriction attenuates age-related increases in hippocampal glial fibrillary acidic protein mRNA. *Neurobiol. Aging* 18, 523–526.
- Mesbah L, Soraya B, Narimane S, Jean PF. (2004). Protective effect of flavonoides against the toxicity of vinblastine cyclophosphamide and paracetamol by inhibition of lipid- peroxidation and increase of liver glutathione. *Haema*; 7: 59-67.
- Meyer, I., and Meyer, P. (1994). Enzyme histochemistry of the growing and adult oligodendrocyte. *Acta Neurologica Scandinavica*, 40, 89-90.
- Michael V. Sofroniew (2009) *Neurosci.*; 32(12): 638–647.
- Mischel RE, Kim YS, Sheldon RA, Ferriero DM. (1997). Hydrogen peroxide is selectively toxic to immature murine neurons in vitro. *Neurosci Lett* 231:17–20.
- Norrell, H., Wilson, C. B., Slagel, D. E., and Clark, D. B. (1994). Leukoencephalopathy following the administration of methotrexate into the cerebrospinal fluid in the treatment of primary brain tumors. *Cancer*, 33, 923-931.
- Pertusa, M., Garcia-Matas, S., Rodriguez-Farre, E., Sanfeliu, C., Cristofol, R., (2007). Astrocytes aged in vitro show a decreased neuroprotective capacity. *J. Neurochem.* 794–805.
- Rajamani R., Manohar S., Muthuvel A., Sheeladevi R., (2006). Oxidative stress induced by methotrexate alone and in the presence of methanol in discrete regions of the rodent brain, retina and optic nerve. *Toxicology Letters* 165: 265–273
- Richter-Landsberg C, Vollgraf U. (1998). Mode of cell injury and death after hydrogen peroxide exposure in cultured oligodendroglia cells. *Exp Cell Res* 244:218–229.
- Roger J., Anna T., Lucy B., Joel L., (1987). Long-term sequelae of cancer treatment on the central nervous system in childhood. *Wiley Online Library*; 15 (5): 241–253
- Rubin, R., Owens, E., and Rall, D. (1998). Transport of methotrexate by the choroid plexus. *Cancer Research*, 28, 689-694.
- Sadun, A.A., (1998). Acquired mitochondrial impairment as a cause of optic nerve disease. *Trans. Am. Ophthalmol. Soc.* 96, 881–923.
- Sakeran MI, Zidan N, Rehman H, Aziz AT, Saggi S. (2014). Abrogation by *Trifolium alexandrinum* root extract on hepatotoxicity induced by acetaminophen in rats. *Redox Rep*; 19 (1): 26-33.
- Samuel, S., Ramanathan, K., Tamilselvan, J., Panneersevam, C., (2005). Protein oxidative damage in arsenic induced rat brain: influence of DL-lipoic acid. *Toxicol. Lett.* 155, 27–34.
- Satoh T, Enokido Y, Aoshima H, Uchimara Y, Hatanaka H. (1997). Changes in mitochondrial membrane

potential during oxidative stress-induced apoptosis. *J Neurosci Res* 50:413–420.

Sener G, Eksioglu-Demiralp E, Cetiner M, Ercan F, Yegen BC. (2006). Beta-glucan ameliorates methotrexate-induced oxidative organ injury via its antioxidant and immunomodulatory effects. *Eur J Pharmacol*; 542 (33): 170-178

Shapiro, W. R., Chernik, N. L., and Posner, J. B. (1993). Necrotizing encephalopathy following intraperitoneal instillation of methotrexate. *Archives of Neurology*, 28, 96- 102.

Takuma K, Matsuda T, Hashimoto H, Asano S, Baba A. (1994). Cultured astrocytes possess Na⁺-Ca²⁺ exchanger. *Glia* 12:36–342.

Tousson E, et al., (2014). P53, Bcl-2 and CD68 expression in response to amethopterin-induced lung injury and ameliorating role of L-carnitine. *Biomed Pharmacotherapy*, 68(5): 631–639

Tousson E, Atteya Z, El-Atrash A, Jeweely O . (2014). Abrogation by Ginkgo Byloba Leaf Extract on Hepatic and Renal Toxicity Induced by Methotrexate in Rats. *Journal of Cancer Research and Treatment*, 2(3): 44-51.

Tsuyosh P, James KB. (1978). A simplified method of quantitating Protein using the Buiret and phenol reagents, *Anal Biochem*; 86: 193-200.

Wallace, K.B., Eells, J.T., Madeira, V.M., Cortopassi, G., Jones, D.P., (1997). Mitochondria-mediated cell injury: Symposium overview. *Fundam. Appl. Toxicol.* 38, 23–37.

Wilson, C. B., and Norrell, H. A., Jr. (1999). Brain tumor chemotherapy with intraperitoneal methotrexate. *Cancer*, 23, 1038-1045.

Yoshida, T., Goldsmith, S.K., Morgan, T.E., Stone, D.J., Finch, C.E., (1996). Transcription supports age-related increases of GFAP gene expression in the male rat brain. *Neurosci. Lett.* 215, 107–110.

Yozai K, Shikata K, Sasaki M, Tone A, Ohga S, Usui H. (2005). Methotrexate prevents renal injury in experimental diabetic rats via anti-inflammatory actions. *J Am Soc Nephrol.*; 16: 3326-3338.

Tsuyosh P, James KB.(1978). A simplified method of quantitating Protein using the Buiret and phenol reagents, *Anal Biochem* 1; 86: 193-200.

Wilson, C. B., and Norrell, H. A., Jr. (1999). Brain tumor chemotherapy with intraperitoneal methotrexate. *Cancer*, 23: 1038-1045.