



Journal of Bioscience and Applied Research

JBAAR

WWW.JBAAR.ORG



Modulation of boldenone induced hepatic and renal toxicity by *Moringa oleifera* in albino rats

Ehab Tousson¹; Ezar Hafez¹; Ahmed Masoud¹; Omer Ershidot²; Reem Ashour*¹

*1. Zoology Department, Faculty of Science, Tanta University, Egypt
2. Al-Balqa' Applied University, Irbid University College, Jordan

(Corresponding author e.mail. reemashour2010@gmail.com)

Abstract

Boldenone is an anabolic androgenic steroid and synthetic derivative of testosterone that was originally developed for veterinary use. Its use is very spread on veterinary medicine because its ability to increase protein synthesis. The aim of this study is to show the toxic effect in liver and kidney caused after the intramuscular injection of boldenone and focus on the role of *Moringa oleifera* as co-treated substance in improving hepatic and renal toxicity of boldenone. 40 adult rats were equally divided into four main groups. Group A injected intramuscularly with olive oil, group B treated only with *Moringa oleifera* 200 mg/Kg body weight, group C injected with boldenone undecylenate only once every three weeks, and co-treated group D which received both intramuscular boldenone undecylenate once every three weeks beside intragastrically dose of of *Moringa* leaf extract twice=0lie/week. The results showed that all the animals in the control groups (A and B) appeared healthy till the end of the experiment. The groups treated with boldenone showed a significant elevation in the levels of serum aspartate transaminase (AST), alanine transaminase (ALT), alkaline phosphatase (ALP), total protein, urea, and creatinine compared to the control group. While the oxidative stress in the groups treated with boldenone showed a significant increase in the level of Malondialdehyde (MDA), nitric oxide (NO), total protein, and total thiol and marked reduction in the level of Glutathione (GSH), Catalase activity (CAT), superoxide dismutase activity (SOD). On the other hand the groups treated with *Moringa oleifera* showed a marked reduction in

the level of ALT, AST, urea, creatinine, MDA, and NO. While the level of GSH, CAT, and SOD showed a significant increase comparing with the control group. These results explain the side effect of boldenone undecylenate on the liver and kidney which may cause hepatic and renal diseases and also the role of *Moringa oleifera* in improving these results.

Keywords: Boldenone, *Moringa oleifera*, Rats, Kidney, Liver, Steroids, Anabolic androgenic steroid.

1 Introduction

Androgens are the hormones which promotes sexual characteristic in men. Also they are largely responsible for the changes which happen during puberty and adolescence (Wilson et al., 2002). Anabolic-androgenic steroids (AAS) are synthetic derivatives of testosterone which used by the bodybuilders to improve the body image according to its ability to increase the protein synthesis (Penatti et al., 2009).

Boldenone undecylenate is one of anabolic steroids which commonly used in the veterinary field. It differs from testosterone in the double bond in the 1,2 position which change its potency and characteristic (Soma et al., 2007). It is known under trade names: Equipoise, Ganabol, Equigan and Ultragan (El-Moghazy et al., 2012). Boldenone is known with its ability of increasing and improving the body mass through many physiological mechanisms which cause nitrogen retention in the body (Ali et al., 2013). It possesses the action to retain calcium, phosphorous,

potassium and chlorides. This action helps to get a better development of the bones only when the dosage is the right one or the recommended one. These constructive processes of mineralization and consolidation allow the bone regeneration in cases of rickets and Osteomalacy (Karila 2003; Hartgens and Kuipers 2004 Soma et al., 2007, Tan and Scally 2009; Bispo et al., 2009;Denham 2012; Alm-Eldeen and Tousson 2012).

In recent years this compound has become a favorite among athletes in order to improve the body image protein synthesis within cells, which results in the buildup of cellular tissue (anabolism), especially in muscles Matinhomae et al., (2014). Also it caused an increase in the red blood cells number which increase blood viscosity allowing more oxygen to be carried to the cells improving the aerobic exercises (Verheyden et al., 2010).

Like other steroids, boldenone has marked side effect as it cause water retention, body fat gain, and gynecomastia due to elevated estrogen level also it cause infertility, hypertension, atherosclerosis, blood clotting hepatic neoplasms and carcinoma, tendon damage, psychiatric and behavioral disorders (Matinhomae et al., 2014). Boldenone has a very long half-life and can show up on a steroid test for up to 1.5 years, due to the undecylate ester attached to the parent steroid. Trace amounts of the drug can be easily detected for months after discontinued use (El-Moghazy et al., 2012; Ali et al., 2013). It has dual effect on humans, directly and indirectly; directly by using this drug by bodybuilders to build muscle and indirectly through veterinary use for meat production (Tousson et al., 2012).

Moringa oleifera Lam (Moringaceae) is a fast growing tree with highly nutritional value (Ezejindu et al., 2014). Regarding to its great value, *Moringa* has been recommended as human food in developing tropical countries because of its ability to combat malnutrition (Paliwal et al., 2011; Atawodi et al., 2010). Various parts of this plants used in therapeutic purposes against variety of diseases like asthma, enlarged spleen and liver, inflammations, gastrointestinal infections, and hepatic and renal disorder (Rajanandh et al., 2012). *Moringa oleifera* has been studied to explore its ability in many disorders such as wound healing, antitumor, and antifertility also it is play important role as hepatoprotective and cardiotoxic stimulants, antiulcer, antihypertensive, cholesterol lowering, and anti-diabetic (Rajanandh et al., 2012).

In addition to all the above values, it is also used in nanotechnology as the leave extracts of *Moringa* is being used in the synthesis of nanoparticles which is safer and more cheaper comparing to the chemical methods. Also it is used in water purification (Arora et al., 2013).

Different parts of *Moringa oleifera* provide us with important minerals, vitamins, amino acids, and various phenolics in addition to zeatin, quercetin, β -sitosterol, caffeoylquinic acid and kaempferol (Nautiyal 2013).

Therefore, our study was designed to investigate the hepatic and renal damage caused by using boldenone undecylenate on male rat and study the role of *Moringa oleifera* in improving these damage.

2 Materials and Methods

Animals

The experiment adhered to the guidelines of the ethical committee of the national research center, Egypt. The experiments were performed on 40 male rats weighing 160-200 g were housed in metal cages under proper environmental conditions at room temperature 20-25°C. Food and water was supplied without restriction.

Preparation of *Moringa oleifera* leaf extraction

Fresh leaves of *Moringa oleifera* were collected and shade dried through exposing it to the air then it was milled and ground into powder. The powder was macerated into absolute alcohol at room temperature. The resulting filtrate was concentrated then evaporated in a water bath using evaporating dish at 45°C. A greenish paste was obtained (Buraimoh et al., 2011).

Experimental design

Rats were divided into 4 groups (10 rats each). Group A rats served as Control which injected intramuscularly with olive oil, group B will treated only with *Moringa oleifera* 200 mg/Kg body weight, group C rats receive 3 doses of 5 mg/Kg body weight boldenone undecylenate intramuscularly injections one dose every three weeks, and group D is the co-treated group which will receive both three doses of 5 mg/Kg body weight boldenone undecylenate one dose every three weeks beside intragastrically dose of 200 mg/Kg body weight twice/week of *Moringa oleifera*. At the end of the experiment, the animals were fasted for 10 hours and euthanized with intravenous injection with sodium pentobarbital and subjected to a complete necropsy.

Sample preparation

Blood samples were individually collected from the inferior vena cava of each rat in non-heparinized glass tubes. Blood sample was centrifuged at 300 rpm for 15 min to separate serum. The collected serum was stored at -18°C.

Biochemical analysis

Blood serum was analyzed to determine the concentration of ALT, AST, alkaline phosphatase, total protein, albumin, urea, creatinine, Na, K, Mg, and also HDL, LDL, total lipid, cholesterol, and triglycerides.

Tissue homogenate

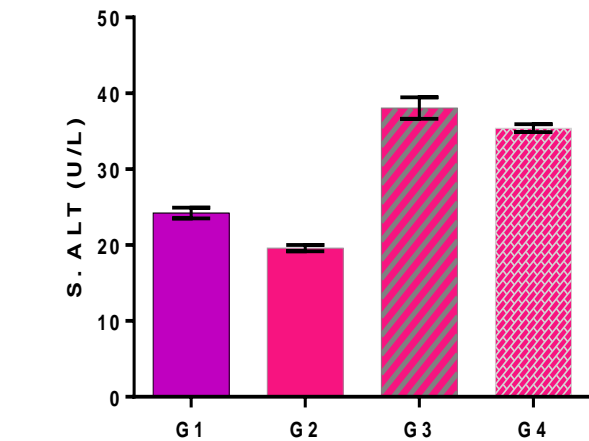
After the animals' dissection liver and kidney tissues were prepared to homogenate by using Potter Elvehjem tissue homogenizer. Tissue was prepared in grinder tube and then centrifuged at 3000 rpm for 15 min. During the homogenization process; the tube should be submersed in an ice bath to maintain the sample at 4°C. The sample frozen immediately stored and placed in a -80°C freezer to be ready for applying the different biochemical estimation (Chattopadhyay 2003; Mesbah et al., 2004 Tousson 2013).

Statistical Analysis

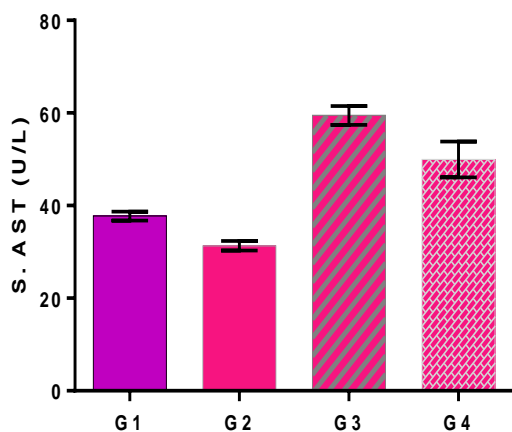
Results obtained were expressed as mean values ± SEM and data was subjected to one way ANOVA to perform statistical analysis to assess significant differences among treatment groups. The criterion for statistical significance was set at $p < 0.05$ for the biochemical data. All statistical analyses were performed using SPSS statistical version 16 software package (SPSS® Inc., USA).

3 Results

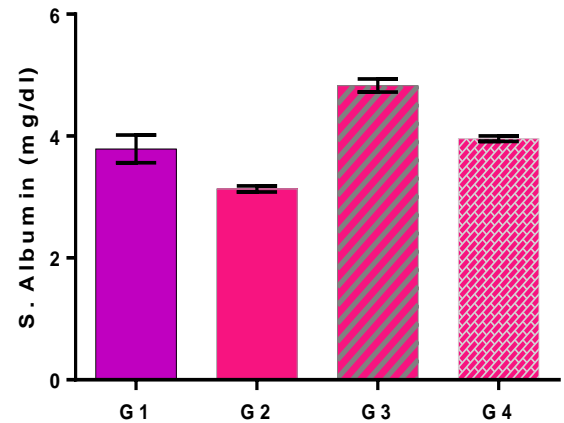
The data presented in Figure 1 showed the changes occur in the level of ALT, AST, Albumin, alkaline phosphatase, and Total protein. As, we found that the level of ALT, AST, alkaline phosphatase, and total protein showed a significant increase in the groups treated with boldenone (G3) comparing with the control group (G1). However, the co-treated group with *M. olifera* (G4) showed significant decrease in the level of ALT, AST, alkaline phosphatase, and total protein comparing with boldenone group (G3).



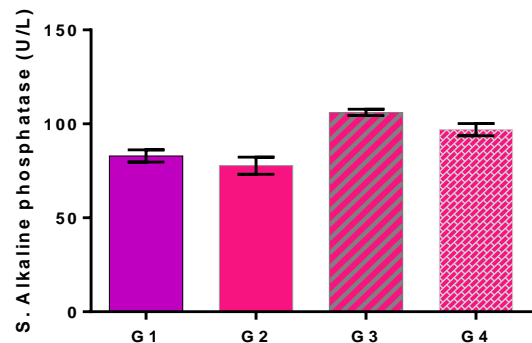
(a)



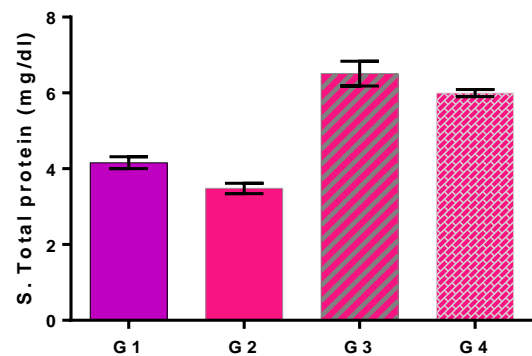
(b)



(c)



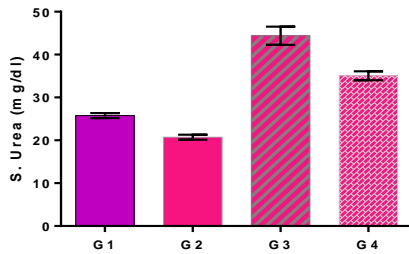
(d)



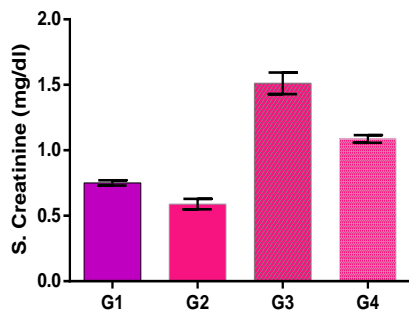
(e)

Figure 1: Data presented in this figure showed the changes in the levels of serum ALT (IU/L), AST (IU/L), albumin (g/l), alkaline phosphatase (u/l), and total protein (mg/dl) in different groups under study. Control group (G1), *M. olifera* (G2), Boldenone group (G3) and co-treated group with *M. olifera* (G4).

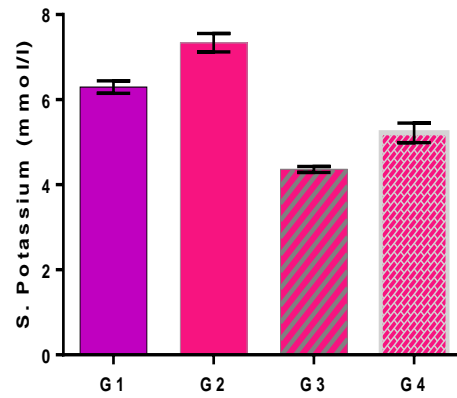
The data presented in Figure 2 showed that the level of urea and creatinine significantly increase ($p < 0.05$) in G3 (boldenone only) comparing with G1 (control group). Also, the level of urea and creatinine in the co-treated group with *Moringa olifera* (G4) showed marked reduction comparing with boldenone only group (G3).



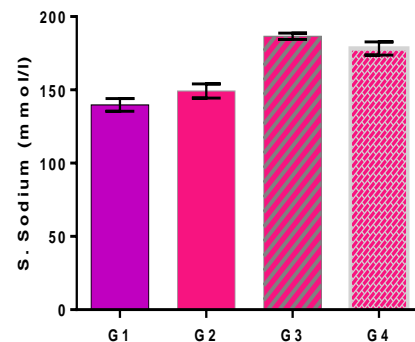
(a)



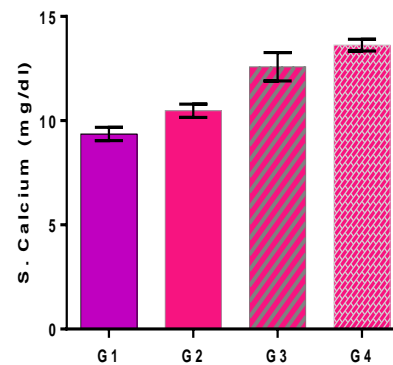
(b)



(a)



(b)



(c)

Figure 2: This figure administered the changes in the level urea and creatinine. Control group (G1), *M. olifera* (G2), Boldenone group (G3) and co-treated group with *M. olifera* (G4).

We found that the level of Na, Ca, and Mg showed marked increase in the groups treated with boldenone comparing with the control group as presented in Figure 3. However, the level of potassium showed marked reduction in boldenone groups comparing with the control group (G1). By investigating the effect of *Moringa olifera* on the level of K, Na, Ca, and Mg, we found that the groups treated with *Moringa olifera* showed marked increase in the level of potassium and calcium comparing with the control group.

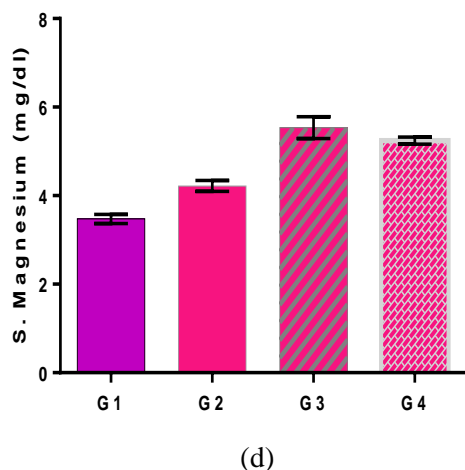


Figure 3: The data presented in this figure administered the changes occur in the levels of K, Na, Ca, and Mg in control group (G1), *M. olifera* (G2), Boldenone group (G3), and co-treated group with *M. olifera* (G4).

Table 1 represents the changes occur in the levels of cholesterol (mg/dl), triglycerides (mg/dl), HDL (mg/dl), LDL (mg/dl) and total lipid. As, a significant increase in the level of cholesterol (mg/dl), triglycerides (mg/dl), LDL (mg/dl) and total lipid was recorded in the groups treated with boldenone comparing with the control group. On the other hand, the level of HDL showed a marked decrease in the groups treated with boldenone comparing with the control group.

Moringa olifera play important role in improving the toxic effect occurred after using boldenone as observed in Table 1. As we found that the level of cholesterol (mg/dl), triglycerides (mg/dl), LDL (mg/dl) and total lipid showed marked reduction in the co-treated group (G4) comparing with the boldenone group (G3).

Table 2 expressed the changes occur in the level of liver and kidney MDA (nmol/g tissue), nitric oxide (NO; $\mu\text{mol/g}$ tissue), Glutathione (GSH;U/g tissue), catalase (mmol/g tissue), superoxide dismutase (U/g), total protein (mg/g) and total thiol (mmol/g tissue) levels in different groups. As, we found that the level of liver and kidney MDA (nmol/g tissue), nitric oxide (NO; $\mu\text{mol/g}$ tissue), total protein (mg/g) and total thiol (mmol/g tissue) showed marked increase in the groups treated with boldenone comparing with the control group. On the other hand, the level of Glutathione (GSH;U/g tissue), catalase (mmol/g tissue), and superoxide dismutase (U/g) showed a marked reduction in groups treated with boldenone comparing with the control group.

By checking the effect of *Moringa olifera*, we found that it plays important role in improving the toxic effect of boldenone. As, we found that the groups treated with *Moringa olifera* showed significant increase in the level of Glutathione (GSH;U/g tissue).

Table 1: Changes in the serum cholesterol (mg/dl), triglycerides (mg/dl), HDL (mg/dl), LDL (mg/dl) and total lipid levels in different groups under study.

	G1	G2	G3	G4
Cholesterol	115.5 ± 0.844*	102.9 ± 0.556**	149.6 ± 1.886	123.2 ± 0.691**
Triglycerides	63.41 ± 0.618*	56.58 ± 0.589*	78.50 ± 1.306	69.79 ± 0.405**
HDL	40.21 ± 0.343*	44.19 ± 0.5195**	30.94 ± 0.1485	35.35 ± 0.484**
LDL	45.23 ± 0.626*	40.49 ± 0.815**	57.48 ± 0.2756	51.16 ± 0.912**
Total lipid	264.0 ± 3.503*	251.1 ± 2.942**	382.9 ± 1.382	348.3 ± 2.868**

Data are expressed as mean ± S.E.M of 10 observations. Significant difference from boldenone group (G3) at * $p < 0.05$. Where G1: Control group; G2: *Moringa* group; G3: Boldenone group; G4: Co-treated boldenone group with *Moringa*.

4 Discussion

Boldenone is known to increase the protein synthesis which affects the body weight through many physiological mechanisms increasing the nitrogen retention. This fact makes boldenone very popular among bodybuilders in order to improve the body image. Also it is used in the veterinary field in the developing countries because of its ability in increasing the body weight. So, boldenone affect human directly and indirectly (Gabr et al., 2009; El-Moghazy et al., 2012). The study of Neri et al. (2011) reported that a prolonged anabolic androgenic steroid administration provokes an increase in the activities of liver lysosomal hydrolases.

Frankenfel et al. (2014), reported in their study that oxidative stress is implicated not only in carcinogenesis, but also in the pathogenesis of a wide range of diseases that can affect liver, heart, kidney and other tissues. Oxidative stress is now recognized to be associated with more than 200 diseases, as well as with the normal aging process (Nelson et al., 2006). Active oxygen species and free radicals play an important role in the pathogenesis of several human diseases, such as rheumatoid arthritis, and cardiovascular diseases including cancer (Paliwal et al., 2011; Hertog et al., 1997).

Moringa oleifera considered as one of the world's most useful tree, as almost every part of the plant can be used for food or has some other beneficial properties (Anamika et al., 2010). The leaves and fruits are found to have hypocholesterolaemic activity in Wistar rats and rabbits, respectively (Ghasi et al., 2000; Mehta et al., 2003). Similarly, the flowers and roots are used in folk remedies, for tumors, the seeds for abdominal tumors, leaves applied as poultice to sores, rubbed on temples for headaches and are said to have purgative properties (Anwar et al., 2007).

Table 2: Changes in liver and kidney MDA (nmol/g tissue), nitric oxide (NO; $\mu\text{mol/g}$ tissue) Glutathione (GSH;U/g tissue), catalase (mmol/g tissue), superoxide dismutase (U/g), total protein (mg/g) and total thiol (mmol/g tissue) levels in different groups under study.

	Test	G1	G2	G3	G4
Liver	MDA	44.31 \pm 0.211*	40.84 \pm 0.203*	53.93 \pm 0.4759	46.52 \pm 0.231*
	GSH	68.65 \pm 0.333*	71.86 \pm 0.336*	61.01 \pm 0.7028	64.44 \pm 0.315*
	Catalase	6.600 \pm 0.0447*	7.360 \pm 0.0427*	4.470 \pm 0.1033	5.400 \pm 0.0422*
	SOD	25.50 \pm 0.156*	27.48 \pm 0.1083**	17.57 \pm 0.3197	21.52 \pm 0.116**
	Total protein	348.2 \pm 1.641*	357.4 \pm 1.673*	412.2 \pm 3.989	382.1 \pm 1.272**
	Total thiol	6.177 \pm 0.0393*	5.834 \pm 0.0276**	6.695 \pm 0.08024	6.241 \pm 0.0309**
kidney	MDA	77.38 \pm 0.557*	70.12 \pm 0.581*	91.54 \pm 1.370	79.10 \pm 0.613*
	GSH	67.26 \pm 0.396**	71.97 \pm 0.472*	55.55 \pm 1.168	61.15 \pm 0.360**
	Catalase	7.906 \pm 0.0349*	8.538 \pm 0.0305*	4.424 \pm 0.07771	5.639 \pm 0.0297**
	SOD	9.614 \pm 0.050*	10.38 \pm 0.0488*	7.125 \pm 0.1061	8.659 \pm 0.04797*
	Total protein	609.7 \pm 2.297	616.9 \pm 2.187**	693.7 \pm 5.661*	652.1 \pm 2.158**
	Total thiol	10.17 \pm 0.0508*	9.115 \pm 0.0469*	13.21 \pm 0.1149	11.21 \pm 0.0449**

Data are expressed as mean \pm S.E.M of 10 observations. Significant difference from the control group (G1) at * $p < 0.05$. Significant difference from Boldenone group (G3) at * $p < 0.05$. Where G1: Control group; G2: *Moringa* group; G3: Boldenone group; G4: Co-treated Boldenone group with *Moringa*.

Moringa oleifera considered as one of the world's most useful tree, as almost every part of the plant can be used for food or has some other beneficial properties (Anamika et al., 2010). The leaves and fruits are found to have hypocholesterolaemic activity in Wistar rats and rabbits, respectively (Ghasi et al., 2000; Mehta et al., 2003). Similarly, the flowers and roots are used in folk remedies, for tumors, the seeds for abdominal tumors, leaves applied as poultice to sores, rubbed on temples for headaches and are said to have purgative properties (Anwar et al., 2007).

The aim of this study is to investigate the effect of boldenone on liver and kidney which showed a marked

alteration in the hepatic and renal functions in groups injected with boldenone and to study the ability of *Moringa* in improving this damage. As *Moringa oleifera* has been reported for its potent antioxidant and free radical scavenging activities in vitro and in vivo (Singh et al., 2009; Sreelatha and Padma 2009; Omobowale et al., 2014; Atawodi et al., 2010). By investigating the effect of boldenone and *Moringa oleifera* on the body weight, we found that the groups treated with both boldenone and *Moringa oleifera* showed a marked increase in the body weight comparing with control group. Our results are in agreement with the studies of (Thabet et al., 2010; Neamat-Allah 2014; Barakat et al., 2015; Tousson et al.,

2012; Halaby et al., 2013; Al-Malki and El Rabey 2015; Ahmed et al., 2014; Hassan et al., 2015).

Our results are not in agreement with the studies of (Oda and El-Ashmawy 2012; Cannizzo et al., 2007; Shabir et al., 2015) as they reported that the treatment with boldenone had no significant effect on the final body weight and also we are not in agreement with (Adedapo et al., 2009; Omobowale et al., 2014), as they proved in their studies that the animals in the control group gained more weight compared to the animals treated with *Moringa oleifera* leaf.

Our results showed a significant decrease in the level of potassium (k) and increase in the level of magnesium (Mg), sodium (Na), calcium (Ca) in the groups treated with boldenone comparing with the control group . As, boldenone promote erythropoietin stimulating factor that, in turn, stimulates the bone marrow growth that leads to an increased production of red blood cells. The release of erythropoietin in the kidneys, cause nitrogen, sodium, potassium, and phosphorus retention and decrease the urinary excretion of calcium. Our result is in agreement with Neamat-Allah (2014) who reported a significant increase in serum level of Ca in the groups treated with boldenone.

The elevation of a given enzyme activity in serum reflects its increase rate of entrance into serum from damaged liver cells like AST, ALT, ALP Ujah et al., (2013). After estimation the serum liver and kidney functions we found that the groups treated with boldenone showed a significant increase in the level of ALT, AST, Albumin, Total protein, urea and creatinine compared to the control group. Our results are in agreement with Alm-Eldeen and Tousson (2012), El-Moghazy et al., (2012), Gabr et al., (2009), Neamat-Allah 2014, Mayada et al., (2015), and Urhausen et al., (2003). While the groups treated with *Moringa oleifera* showed marked reduction in the level of ALT, AST, alkaline phosphatase, albumin, urea and creatinine. Our results are in agreement with the studies of Saalu et al., (2012), Al-Malki and El Rabey (2015), Sheikh et al., (2014), Das et al., (2012), Fakurazi et al., (2012), Aja et al., (2013), Omobowale et al., (2014).

Beside the toxic and hormonal side effects of boldenone, our result revealed a marked elevation in the level of total lipid, LDL, cholestrol and triglycerides after the intramuscular injection of boldenone, whereas the level of HDL showed a significant decrease comparing with the control group. Our results are in agreement with the studies of El-Moghazy et al., (2012) and Shabir et al., (2015). Our results are note in agreement with Hartgens and Kuipers (2004) as they reported that the level of triglyceride did not show any alteration in of serum triglyceride level but we agreed with them in the significant increase in the level of LDL and the significant decrease in the level of HDL.

By evaluating the effect of *Moringa oleifera* on serum lipid profile, we found a significant increase in the level of serum HDL parallel with significant reduction in the level of serum LDL and triglyceride. Our result in agreement with Okwari et al (2015), Prasanna Kumar and

Mandapaka (2013), Ahmed et al., (2014), Halaby et al., (2013), and Jain et al., (2010).

Boldenone treatment caused an oxidative stress situation as indicated by enhanced MDA, SOD, and GSH extent. Our results recorded significant increase in the level of MDA, total protein, and total thiol. While a significant decrease in the level of GSH, CAT, and . Our results are in agreement with Mayada e al., (2015), El-Moghaz et al., (2012), Frankenfeld et al., (2014).

By evaluating the effect of *Moringa oleifera* in improving the side effect caused by boldenone, we found that the level of MDA showed marked reduction comparing with the group treated with boldenone. While the level of GSH, CAT, and SOD showed marked increase comparing with the group treated with boldenone and the control group. These results are in agreement with Al-Malki and El Rabey (2015), Ahmed et al., (2014), Fakurazi et al., (2012), Das et al., (2012), and Rajanandh et al., (2012).

In conclusion, our results prove that using boldenone can cause serious damage to liver and kidney estimated by marked elevation in MDA, LDL, serum activities of ALT, AST, ALP, and level of urea and creatinine. Also, we Administration of *Moringa oleifera* improved the damage caused by boldenone beside its protective potentials on liver and kidney.

Conflicts of interest

The authors had no conflicts of interest to declare in relation to this article. This research received no specific grant from any funding agency in the public, commercial, or not-for-profit sectors

5 References

- Adedapo AA, Mogbojuri OM, Emikpe BO.(2009). Safety evaluations of the aqueous extract of the leaves of *Moringa oleifera* in rats. Journal of Medicinal Plants Research ; 3: 586-91.
- Ahmed HH, Metwally FM., Rashad H, Zaazaa AM, Ezzat SM, Salama MM.(2014). *Moringa oleifera* offers a Multi-Mechanistic Approach for Management of Obesity in Rats. Int. J. Pharm. Sci. Rev. Res ; 29: 98-106.
- Aja PM, Nwafor EJ, Ibiam AU, Orji OU, Ezeani N, Nwali BU(2013). Evaluation of Anti-diabetic and Liver Enzymes Activity of Aqueous Extracts of *Moringa oleifera* and *Bridelia ferruginea* Leaves in Alloxan Induced Diabetic Albino Rats. International Journal of Biochemistry Research & Review ; 3: 248-58.
- Ali EM., Tousson E. Abd El Daim HA.(2013). Effects of Short and Long Term Growth Promoter Boldenone Undecylenate Treatments on Antioxidant Enzyme Activities and Oxidative Stress Markers in Rabbit Muscles. Pharmacologia ; 4: 576-81.
- Al-Malki AL. and El Rabey HA.(2015). The Antidiabetic Effect of Low Doses of *Moringa oleifera* Lam. Seeds on Streptozotocin Induced Diabetes and Diabetic Nephropathy in Male Rats. Biomed Res Int; 2015: 13 pages.

- Alm-Eldeen SA. and Tousson E.(2012). Deterioration of glomerular endothelial surface layer and the alteration in the renal function after a growth promoter boldenone injection in rabbits. *Human and Experimental Toxicology* ; 31: 465–72.
- Anamika K, Krebs AR, Thompson J, Poch O, Devys D, Tora L.(2010). Lessons from genome-wide studies: An integrated definition of the coactivator function of histone acetyl transferases. *Epigenetics Chromatin* ; 3:18.
- Anwar F, Latif S, Ashraf M, Gilani AH.(2007). *Moringa oleifera*: a food plant with multiple medicinal uses. *Phytother Res*; 21: 17-25
- Arora DS, Onsare JG, Kaur H.(2013). Bioprospecting of *Moringa* (Moringaceae): Microbiological Perspective. *Journal of Pharmacognosy and Phytochemistry*; 1: Page 194.
- Atawodi SE, Atawodi JC, Idakwo GA, Pfundstein B, Haubner R, Wurtele G, Bartsch H, Owen RW.(2010). Evaluation of the polyphenol content and antioxidant properties of methanol extracts of the leaves, stem, and root barks of *Moringa oleifera* Lam. *J Med Food*; 13: 710-6.
- Barakat LAA, Tousson E, Ibrahim W, Abd El-Hakeem A. (2015). Role of propolis in improving hepatic and renal damage in boldenone undecylenate in male rats. *American Journal of Biological Chemistry*; 3: 8-15.
- Bispo M, Valente A, Maldonado R, Palma R, Glória H, Nóbrega J. et al., (2009) Anabolic steroid-induced cardiomyopathy underlying acute liver failure in a young bodybuilder. *World Journal of Gastroenterology*; 15: 2920-22.
- Buraimoh AA, Bako IG, Ibrahim FB. (2011). Hepatoprotective Effect of Ethanolic Leave Extract of *Moringa oleifera* on the Histology of Paracetamol Induced Liver Damage in Wistar Rats. *International Journal of Animal and Veterinary Advances* ; 3: 10-3.
- Cannizzo TF, Zancanaro G, Spada F, Mulasso C, Biolatti B. (2007). Pathology of the Testicle and Sex Accessory Glands Following the Administration of Boldenone and Boldione as Growth Promoters in Veal Calves. *J Vet Med Sci* ; 69: 1109–16.
- Chattopadhyay RR. (2003). Possible mechanism of hepatoprotective activity of *Azadirachta indica* leaf extract: Part II. *Journal of Ethnopharmacology* ; 89: 217-219.
- Das N, Sikder K, Ghosh S, Fromenty B, Dey S. (2012). *Moringa oleifera* Lam. leaf extract prevents early liver injury and restores antioxidant status in mice fed with high-fat diet. *Indian J Exp Biol* ; 50: 404-12.
- Denham BE.(2012). Anabolic-androgenic steroids and adolescents: recent developments. *J Addict Nurs*; 23: 167-71.
- El-Moghazy M, Tousson E, Sakeran MI. (2012).Changes in the hepatic and renal structure and function after a growth promoter boldenone injection in rabbits. *Animal Biology*; 62: 171–80.
- Ezejindu DN, Udemezue OO, Akingboye AJ. (2014).Renoprotective effects of *moringa oleifera* leaf extract on the kidneys of adult wistar rats. *American Journal of Engineering Research (AJER)* ; 3:157-61.
- Fakurazi S, Sharifudin SA, Arulselvan P. (2012).*Moringa oleifera* Hydroethanolic Extracts Effectively Alleviate Acetaminophen-Induced Hepatotoxicity in Experimental Rats through Their Antioxidant Nature. *Molecules* 17: 8334-50.
- Frankenfeld SP, Oliveira LP, Ortenzi VH, Rego-Monteiro IC, Chaves EA, Ferreira AC, et al., (2014).The Anabolic Androgenic Steroid Nandrolone Decanoate Disrupts Redox Homeostasis in Liver, Heart and Kidney of Male Wistar Rats. *PLOS ONE* ; 9: e0102699.
- Gabr F, Abo El-Maaty T, Amal M, Aotifa AM. (2009).Effects of growth promoter boldenone undecylenate on weaned male lambs. *Nature and Science*; 7: 61-69.
- Ghasi S, Nwobodo E, Ofili JO. (2000).Hypocholesterolemic effects of crude extract of leaf of *Moringa oleifera* Lam in high-fat diet fed Wistar rats. *J Ethnopharmacol* 69: 21-5.
- Halaby MS, Elmetwaly EM. Omar AAA. (2013). Effect of *Moringa Oleifera* on serum lipids and kidney function of hyperlipidemic rats. *Journal of Applied Sciences Research*; 9: 5189-98.
- Hartgens F. and Kuipers H. (2004).Effects of androgenic-anabolic steroids in athletes. *Sports Med*; 34: 513-54.
- Hassan HMA, El-Moniary MM, Hamouda Y, El-Daly EF, Youssef AW, Abd El-Azeem NA. (2016). Effect of Different Levels of *Moringa oleifera* Leaves Meal on Productive Performance, Carcass Characteristics and Some Blood Parameters of Broiler Chicks Reared Under Heat Stress Conditions. *Asian Journal of Animal and Veterinary Advances* ; 11: 60-6.
- Hertog MGL, Sweetnam PM, Fehily AM, Elwood PC, Kromhout D. (1997). Antioxidant flavonols and ischemic heart disease in a Welsh population of men: the Caerphilly study. *Am J Clin Nutr*; 65: 1489-94.
- Jain PG, Patil SD, Haswani NG, Girase MV, Suran SJ. (2010). Hypolipidemic activity of *Moringa oleifera* Lam., Moringaceae, on high fat diet induced hyperlipidemia in albino rats. *Brazilian Journal of Pharmacognosy* ; 20: 969-73.
- Matinhomae H, Ziaolhagh SJ, Azarbayjani MA, Piri M. (2014).Effects of Boldenone consumption and resistance exercise on hepatocyte morphologic damages in male wistar rats. *Euro. J. Exp. Bio.* ; 4: 211-4.
- Mayada RF, Taghred MS, Haytham AA. (2015). Boldenone-induced apoptotic, structural, and functional alterations in the liver of rabbits. *World Rabbit Science* ; 23: 39-46.
- Mehta LK, Balaraman R, Amin AH., Bafna PA, Gulati OD. (2003). Effect of fruits of *Moringa oleifera* on the lipid profile of normal and hypercholesterolaemic rabbits. *J Ethnopharmacol.*; 86: 191-5.
- Mesbah L, Soraya B, Narimane S, Jean PF. (2004). Protective effect of flavonoides against the toxicity of vinblastine cyclophosphamide and paracetamol by inhibition of lipid- peroxidation and increase of liver glutathione. *Haema* ; 7: 59-67.

- Nautiyal OH. (2013). Natural Products from Plant, Microbial and Marine Species. International Journal of science and technology. The Experiment ; 10: page 631.
- Neamat-Allah ANF. (2014). Effect of Boldenone Undecylenate on Haematological and Biochemical Parameters in Veal Calves. Global Veterinaria ; 13: 1092-6.
- Nelson SK, Bose SK, Grunwald GK, Myhill P, McCord JM. (2006). The induction of human superoxide dismutase and catalase in vivo: A fundamentally new approach to antioxidant therapy. Free Radic Biol Med; 40: 341-7.
- Neri M, Bello S, Bonsignore A, Cantatore S, Riezzo I, Turillazzi E, Fineschi V. (2011). Anabolic androgenic steroids abuse and liver toxicity. Mini Rev Med Chem; 11:430-7.
- Oda SS. and El-Ashmawy IM. (2012). Adverse effects of the anabolic steroid, boldenone undecylenate, on reproductive functions of male rabbits. Int J Exp Pathol.; 93: 172-8.
- Okwari OO, Alagwu EA, Dasofunjo K, Okwari KO, Obi L. (2015). Effect of Aqueous Leaf Extract of Moringa Oleifera on Some Renal Function Indices of Rats. International Journal of Pharma Sciences and Research (IJPSR) ; 6: 777-82.
- Omobowale TO, Oyagbemi AA, Abiola JO, Azeze IO, Adedokun RA, Nottidge HO. (2014). Effect of Chronic Administration of Methanol Extract of Moringa Oleifera on Some Biochemical Indices in Female Wistar Rats. Niger J Physiol Sci; 29: 107-11.
- Paliwal R, Sharma V, Pracheta, Sharma S, Yadav S, Sharma S. (2011). Anti-nephrotoxic effect of administration of Moringa oleifera Lam in amelioration of DMBA-induced renal carcinogenesis in Swiss albino mice. Biology and Medicine; 3: 27-35.
- Prasanna KK, and Mandapaka RT. (2013). Effect of Moringa Oleifera On Blood Glucose, Ldl Levels In Types II Diabetic Obese People. Innovative Journal of Medical and Health Science ; 3: 23-5.
- Penatti CA, Costine BA, Porter DM, Henderson LP. (2009). Effects of Chronic Exposure to an Anabolic Androgenic Steroid Cocktail on α 5-Receptor Mediated GABAergic Transmission and Neural Signaling in the Forebrain of Female Mice. Neuroscience ; 161: 526-37.
- Rajanandh MG, Satishkumar MN, Elango K, Suresh B. (2012). Moringa oleifera Lam. A herbal medicine for hyperlipidemia: A pre-clinical report. Asian Pac J Trop Dis; 2: S790-5.
- Saalu LC, Ogunlade B, Ajayi GO, Oyewopo AO, Akunna GG, Ogunmodede OS. (2012). The hepatoprotective potentials of Moringa oleifera leaf extract on alcohol-induced hepato-toxicity in Wistar rat. American Journal Biotechnology and Molecular Sciences; 2: 6-14.
- Shabir N, Malik H, Sajjad S, Abbas MN. (2015). Effect of Nandrolone Decanoate, Boldenone Undecylenate on Renal Status of Rabbits (*Oryctolagus cuniculus*). Global Veterinaria ; 14: 432-8.
- Sheikh A, Yeasmin F, Agarwal S, Rahman M, Islam K, Hossain E, et al., (2014). Protective effects of Moringa oleifera Lam. leaves against arsenic-induced toxicity in mice. Asian Pac J Trop Biomed; 4: S353-S358.
- Singh BN, Singh BR, Singh RL, Prakash D, Dhakarey R, Upadhyay G. et al., (2009). Oxidative DNA damage protective activity, antioxidant and anti-quorum sensing potentials of Moringa oleifera. Food Chem Toxicol; 47: 1109-16.
- Soma LR, Uboh CE, Guan F, McDonnell S, Pack J. (2007). Pharmacokinetics of boldenone and stanozolol and the results of quantification of anabolic and androgenic steroids in race horses and nonrace horses. J Vet Pharmacol Ther; 30: 101-8.
- Sreelatha S. and Padma PR. (2009). Antioxidant Activity and Total Phenolic Content of Moringa oleifera Leaves in Two Stages of Maturity. Plant Foods Hum Nutr; 64: 303-11.
- Tan RS. and Scally MC. (2009). Anabolic steroid-induced hypogonadism – Towards a unified hypothesis of anabolic steroid action. Med Hypotheses ; 72:723-8
- Thabet NS, Abdelrazek EM, Ghazy EW, Elballal SS. (2010). Effect of the anabolic steroid, Boldenone Undecylenate on reproductive performance of male rabbits. J Reprod Infertil; 1: 8-17.
- Tousson E. (2013). Histopathological alterations after a growth promoter boldenone injection in rabbits. Toxicol Ind Health ; 32: 299-305.
- Ujah OF, Ujah IR, Johnson JT, Ekam VS, Udenze J EC. (2013). Hepatoprotective property of ethanolic leaf extract of Moringa oleifera on carbon tetrachloride (CCl4) induced hepatotoxicity. Journal of Natural Product and Plant Resources ; 3:15-22.
- Urhausen A., Torsten A. and Wilfried K. (2003). Reversibility of the effects on blood cells, lipids, liver function and hormones in former anabolic-androgenic steroid abusers. J Steroid Biochem Mol Biol ; 84: 369-75.
- Verheyden K, Noppe H, Zorn H, Van Immerseel F, Bussche JV, Wille K, et al., (2010). Endogenous boldenone-formation in cattle: Alternative invertebrate organisms to elucidate the enzymatic pathway and the potential role of edible fungi on cattle's feed. J Steroid Biochem Mol Biol; 119: 161-70.
- Wilson JD, Leihy MW, Shaw G, Renfree MB. (2002). Androgen physiology: unsolved problems at the millennium. Mol Cell Endocrinol ; 198: 1-5.