



JBAAR



Journal of Bioscience and Applied Research

WWW.JBAAR.ORG

The possible anti-inflammatory role of the blue green algae, *Aphanizomenon flos-aquae* on liver of adult male rats

Samir Atea Mohammed¹, Hemmat Mansour Abdelhafez¹, Fatma Ahmed Eid¹
Ola Mohammed Abdel-Raouf², Rasha Mohammed Ibrahim¹

1. Department of Zoology, Faculty of Science, Al- Azhar University, Cairo, Egypt.
2. Pharmacology Department, National Organization for Drug Control and Research (NODCR), Cairo, Egypt.

(Corresponding author email: fatmaeid22@yahoo.com)

Abstract

Aphanizomenon flose-aquae (AFA) is a fresh water unicellular blue green microalgae like *Spirulina*, but most AFA is harvested from the wild in volcanic regions leading to high levels of trace minerals. *Aphanizomenon flos-aquae* have been traditionally used for over 25 years for its health-enhancing properties. To investigate the possible anti-inflammatory role of *Aphanizomenon flose-aquae*, rats were injected with carrageenan. The current experiment was carried out on 48 adult male albino rats (*Rattus rattus*). Rats were randomly and equally categorized into four groups: 1) Group C: control rats left without treatment; 2) Group Carr: rats were injected with carrageenan and left for 21 days ; 3) Group AFA rats were orally administrated *Aphanizomenon flos- aquae* (AFA) extract (94.5 mg/kg body weight /day) for 21 days and 4) Group AFA+ Carr: rats were injected with carrageenan and treated with 94.5 mg/kg body weight AFA extract daily post six hours after carrageenan injection for 21 days. The experimental rats were sacrificed after 5 and 21 days post- treatment. Results: injection of rats with carrageenan induced a significant decreases in red blood cells (RBCs) count, hemoglobin concentration (Hb) and hematocrit value (Hct) as compared to the control group. In contrast, the levels of white blood cells (WBCs) count, alanine aminotransferase (ALT), aspartate aminotransferase (AST) and alkaline phosphatase (ALP) activities were significantly increased; this was accompanied by histopathological and histochemical changes such as aggregated lymphocytes in and around the portal areas with hemorrhagic areas ,highly dilated and congested hepatic portal veins which contained hemolysed blood cells, dilated and distorted wall of the central veins with ruptured and delaminated endothelial lining of them. elongated and distorted walls of the bile

ducts which showed highly increased proliferation, numerous vacuolated hepatocytes and highly increased kupffer cells. Highly increased collagen fibres were noticed in and around the portal area, inside the hepatic portal vein and also beside the central vein. In addition, injection of rats with carrageenan induced a significant increase in PAS+ve materials, total protein and amyloid protein. Meanwhile, treatment of rats with AFA for 5 and twenty one days did not exhibit a toxic effect on the liver. Also, treatment of rats with AFA post-carrageenan injection exhibited anti-inflammatory activity and improved hematological parameters and liver function profile. In conclusion, using *Aphanizomenon flos- aquae* as a natural agent showed a strong anti-inflammatory role.

Keywords: *Aphanizomenon flos- aquae*, Carrageenan, Inflammation and Rats.

1 Introduction

Carrageenan emerged as a fascinating compound has a wide spectrum of interference with the biological systems. Although the safety and toxicity profile of carrageenan is well studied, it was reported that different carrageenan subtypes (iota-, lambda- and kappa-carrageenan) can produce different biological and toxicological effects (Mc-kim, 2014; Weiner, 2014). It is often used for the testing of anti-inflammatory agents (Sini *et al.*, 2010). There is a worldwide trend to natural resources, which are culturally acceptable and economically viable. Among the important and effective drugs used to treat chronic diseases are derived from plants and certain species of cyanobacteria (Yeh *et al.*, 2006 ; Nahin *et al.*, 2009 ; El-Depsi, 2016). Blue-green algae (BGA), also known as cyanobacteria, among the phylum of bacteria that utilize photosynthesis to obtain energy. They are technically classified as bacteria and share properties with them (Schaap *et al.*, 2012). They are nutritious natural

products rich in essential amino acids, γ -linolenic acid, fibres, B vitamins, calcium, iron, phosphorous, pigments such as β -carotene, xanthophylls, chlorophyll and other bioactive compounds (Regunathan and Wesley, 2006). Singh *et al.* (2005) and El-Depsi (2016) reported that BGA have antiviral, antitumor, antioxidant, anti-inflammatory, anti-allergic, anti-diabetic and antibacterial properties as well as lipid-lowering effects. *Aphanizomenon flos-aquae* (AFA) is a fresh water unicellular blue-green alga that is consumed as a nutrient-dense food source and for its health-enhancing properties (Benedetti *et al.*, 2004 ; Scoglio *et al.*, 2014). *Aphanizomenon flos-aquae* as a species has both nontoxic and toxic forms. Most sources worldwide are toxic, containing both hepatic and neuroendotoxins. *Aphanizomenon flos-aquae* from Klamath Lake is a non-toxic type of algae of the cyanobacteria phylum (Jensen *et al.*, 2001). *Aphanizomenon flos-aquae* have gained popularity in USA, Germany, Canada, Korea, Japan and Austria. It contains 20 antioxidants, 68 minerals, 70 trace elements, all amino acids, B vitamins and important enzymes (Chakdar *et al.*, 2012). Also, the most common BGA, *Spirulina platensis* (SP) and *Aphanizomenon flos-aquae* (AFA) were found to have antioxidant (Venkatesan *et al.*, 2012), anti-inflammatory and hypolipidemic properties (Tiniakos *et al.*, 2010 ; Yang *et al.*, 2011). *Aphanizomenon flos-aquae* is an important source of the blue photosynthetic pigment phycocyanin (PC), which has been described as a strong antioxidant and anti-inflammatory agent (Reddy *et al.*, 2000 ; Scoglio *et al.*, 2009 ; Benedetti *et al.*, 2010).

2 Materials and Methods

Experimental animals

A total of forty eight mature male albino rats weighing about 120-160 g. each were used in the present study. The animals were kept in the laboratory for two weeks before the experimental work. They were housed in especially designed and cleaned cages, 6 rats per cage and maintained under controlled conditions of temperature, light (12 hours light: 12 hours dark) and good ventilation. They were fed normal diet and water *ad libitum*.

Experimental design

The experimental animals were divided into 4 groups. These groups were

- Group 1- Untreated normal control rats (C).
- Group 2- Rats were injected with carrageenan and left for 21 days (Carr).
- Group 3- Rats were orally administrated *Aphanizomenon flos-aquae* (AFA) extract (94.5 mg/kg body weight /day) for 21 days.
- Group 4- Rats were injected with carrageenan and treated with 94.5 mg/kg body weight AFA extract daily post six hours after carrageenan injection for 21 days (AFA+ Carr).

The experimental rats were sacrificed after 5 and 21 days post- treatment.

Inflammatory model (rat paw edema)

Carrageenan (Carr) was obtained from Sigma Company. Type IVEC No. 232-953-5. Carrageenan solution was prepared as 1% suspension in saline, where each animal was injected by 0.1 ml of carrageenan solution in subplanter tissue of the left hind paw (Ghosh *et al.*, 2000) for induction of experimental inflammation.

Preparation of *Aphanizomenon flos-aquae* (AFA) extract

AFA-Klamath capsules (350 mg) purchased from German Egyptian Pharmaceutical Company. AFA capsule were opened and dissolved in distilled water. The drug was administrated orally by gastric tube at a dose of 94.5 mg/kg body weight/day for 21 days. The dose for the rat was calculated according to the Paget's formula on the basis of the human dose (Paget and Barns, 1964).

At the end of experiment, peripheral blood was collected for hematological parameters and serum was separated by centrifugation at 3000 rpm for 10 minutes for biochemical analysis. Livers of rats were carefully removed and prepared for various histopathological and histochemical studies.

Hematological studies

Red blood cells (RBCs) were counted visually according to the method of Dacie and Lewis (1991). Hemoglobin concentration was determined according to the method of Drabkin and Austin (1932). Hematocrit value was determined according to the method of Rodak (1995) using heparinized capillary tubes. White blood cells (WBCs) were counted visually according to the method of Mitruka and Rawnsley (1977).

Biochemical parameters

The activities of serum alanine aminotransferase (ALT) and aspartate aminotransferase (AST) were assayed by the kinetic method using available commercial kits (Spinreact, Spain) according to the method described by Young and Friedman (2001). The activities of alkaline phosphatase (ALP) in serum were assayed by the kinetic method using available commercial kit (Spinreact, Spain) according to the International Federation of Clinical Chemistry (IFCC) (Schumann *et al.*, 2002).

Histopathological and histochemical techniques

Livers of all groups were washed in saline and fixed in 10% neutral formalin, followed by dehydration in ascending grades of alcohol, clearing in xylene and embedding in paraffin wax. Sections were then cut at 5 μ thickness and stained by haematoxylin and eosin stain for histopathological study according to the method reported by Bancroft and Gamble (2002). Collagen fibres were stained by using Mallory's trichrome stain (Pears, 1977). Polysaccharides were detected by using periodic acid Schiff's (PAS) reagent (Drury and Wallington, 1980). Total proteins were detected by using mercuric bromophenol blue method (Mazia *et al.*, 1953). Amyloid- β protein was detected by Congo red technique (Valle, 1986).

Quantitative histochemical analysis

The optical density of histochemical stained sections in liver tissue for carbohydrates, total protein and Amyloid- β

protein of the control and treated groups was recorded using IPWIN 32 image analysis software.

Statistical analysis

Statistical analyses were performed using analyses of variance (ANOVA) according to Snedecor and Cochran (1980). The data were processed and analyzed using the SPSS software (Statistical Analysis for Social Science, Version 8). Significant differences between treatment means were determined by student t-test. Data were presented as mean \pm SE and $P < 0.05$ was considered statistically significant.

3 Results

1-Hematological results

- Red blood cells (RBCs) count

Injection of rats with carrageenan induced a significant decrease in RBCs count all over the experimental periods as compared to the control group. At the same time oral administration of albino rats with AFA alone showed non-significant changes in the mean values of RBCs, while rats treated with AFA post-carrageenan injection resulted in non-significant decreases in RBCs count on the five and twenty one days post-treatment as compared to the control group as shown in fig. 1.

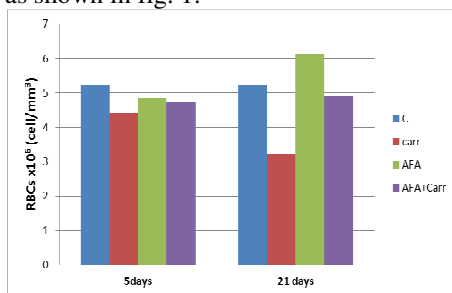


Figure 1- Showing the mean values of red blood cells (RBCs $\times 10^6$ cell/mm³) in the control and the different experimental groups (Carr, AFA and AFA+ Carr) at different intervals (5 and 21 days post-treatment).

-Estimation of hemoglobin (g / dl) concentration

The present results showed that injection of rats with carrageenan induced a significant decrease in hemoglobin concentration at 5 and 21 days post-t carrageenan injection as compared to the control group. While non-significant changes in Hb concentration was observed in AFA or AFA post-carrageenan injection during the two experimental periods (Fig. 2).

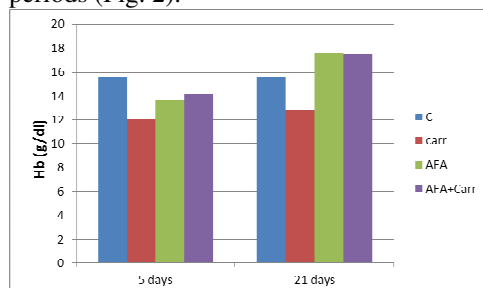


Figure 2- Showing the mean values of hemoglobin (Hb g/dl) concentration in the control and the different experimental groups (Carr, AFA and AFA+ Carr) at different intervals (5 and 21 days post-treatment).

-Measurement of hematocrit (Hct) value

Rats injected with carrageenan showed highly significant decrease ($P < 0.01$) in the mean value of blood Hct at 5 days and a very highly significant decrease ($P < 0.001$) after 21 days as compared to the control group. On the other hand, rats treated with AFA alone or AFA post-carrageenan injection showed non-significant changes ($P > 0.05$) in Hct mean values all over the experimental period (Fig. 3).

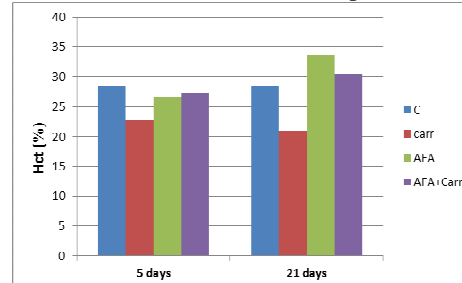


Figure 3- Showing the mean values of hematocrit percent (Hct%) in the control and the different experimental groups (Carr, AFA and AFA+ Carr) at different intervals (5 and 21 days post-treatment).

-White blood cells (WBCs) count

Injection of rats with carrageenan induced a significant increase ($P < 0.05$) in the mean value of WBCs after 5 days post carrageenan injection as compared to the control group while, very highly significant increase ($P < 0.001$) was observed in the mean value of WBCs after 21 days post-treatment. Also, treatment of rats with AFA alone or AFA+carr showed non-significant increase in mean values of WBCs after 5 and 21 days post-treatment as compared to the control group. (Fig. 4).

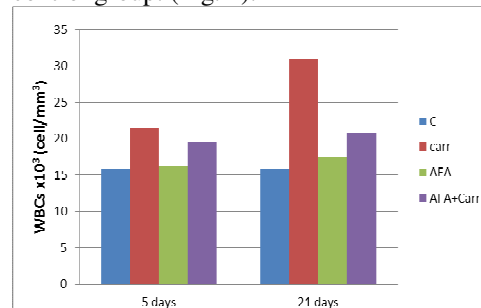


Figure 4 - Showing the mean values of white blood cells (WBCs $\times 10^3$ cell/mm³) in the control and the different experimental groups (Carr, AFA and AFA+ Carr) at different intervals (5 and 21 days post-treatment).

2-Biochemical parameters

-Serum alanine aminotransferase activity

Rats injected with carrageenan exhibited a significant increase ($P < 0.05$) in the mean values of serum ALT level on the five and twenty one days post- carrageenan injection in comparison with the control group. The present results also showed that there is non-significant decrease in the mean values of serum ALT in rats treated with AFA alone on the 5 and 21 days post-treatment as compared to the control group. On the other hand, treatment of rats with carrageenan and AFA resulted in a non-significant increase in the mean values of serum ALT during the two

experimental periods in comparison with that obtained from the control group (Fig. 5).

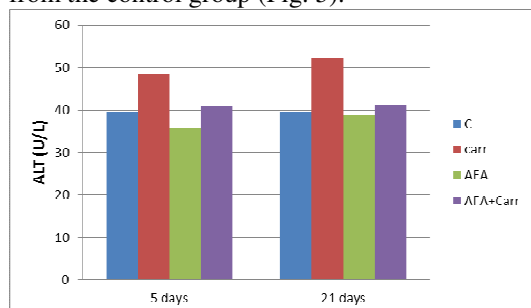


Figure 5 - Showing the mean values of serum alanine aminotransferase (ALT, U/L) in the control and the different experimental groups (Carr, AFA and AFA+ Carr) at different intervals (5 and 21 days post-treatment).

-Serum aspartate aminotransferase activity

Injection of rats with carrageenan recorded a significant increase ($P < 0.05$) in the mean values of serum AST after 5 and 21 days post-carrageenan injection as compared to the control value. On the other hand, non-significant increases in the mean values of serum AST were recorded in groups treated with AFA alone or AFA post-carrageenan injection all over the experimental periods as compared to the control group (Fig. 6).

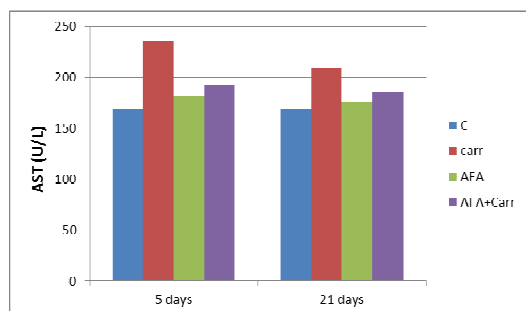


Figure 6 - Showing the mean values of serum aspartate aminotransferase activity (AST, U/L) of the control and the different experimental groups (Carr, AFA and AFA+ Carr) at different intervals (5 and 21 days post-treatment).

Serum alkaline phosphatase activity

Carrageenan injection to the rats induced a significant increase ($P < 0.05$) in the mean values of serum ALP level all over the experimental periods in comparison with the control group. While, non-significant decreases were realized in the mean values of serum ALP level in AFA group after 5 and 21 days post-treatment when compared to the control group. However, non-significant increases were observed in the mean values of serum ALP in group treated with AFA post-carrageenan injection after 5 and 21 days post-treatment as compared to the control group (Fig. 7).

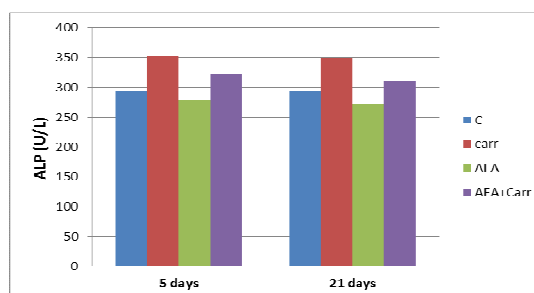


Figure 7- Showing the mean values of serum alkaline phosphatase (ALP, U/L) in the control and the different experimental groups (Carr, AFA and AFA+Carr) at different intervals (5 and 21 days post-treatment).

3-Histopathological and histochemical observation

Examination of the liver tissue five days post-carrageenan injection showed many deleterious changes in the liver tissue, such as aggregated lymphocytes in and around the portal areas with hemorrhagic areas, highly dilated and congested hepatic portal veins which contained hemolysed blood cells, elongated and distorted walls of the bile ducts which show highly increased proliferation, numerous vacuolated hepatocytes and highly increased kupffer cells (Figs. 8 B & C). After twenty one days following carrageenan injection, liver sections showed highly dilated and distorted wall of the central veins with ruptured and delaminated endothelial lining of them. Central veins contain hemolysed blood cells inside them (Figs. 8D&E). Highly increased collagen fibres were noticed in and around the portal area, inside the hepatic portal vein and also beside the central vein (Figs. 9B & C & Figs. 9D&E) after five and twenty one days post carrageenan injection respectively.

Normal histological appearance of the liver tissue of AFA group could be detected in figs. 8F & G after 5 and 21 days post-treatment respectively, with normal distribution of collagen fibres around the hepatocytes, the central vein, in the portal area and the blood sinusoids (Figs. 9F & G) after five and twenty one days post treatment respectively.

On the other hand, treatment of rats with carrageenan and AFA showed somewhat normal appearance of most hepatocytes in the liver tissue examined five days post-carrageenan injection, but some hepatocytes contained pyknotic nuclei with lymphocytic infiltration in and around the portal area (Fig. 8H). AFA+ Carr group after twenty one days of treatment showed improvement of architecture of the liver tissue (Fig. 8I) this was accompanied by normal distribution of collagen fibres (Figs. 9H & I) after five and twenty one days post treatment respectively.

Quantitative histochemical measurements

The present study revealed that the group of rat's injected with carrageenan exhibited a significant increase in the mean value of PAS positive materials all over the experimental periods. While, rats administrated AFA alone or AFA post-carrageenan injection exhibited a non-significant increase in the mean value of PAS positive materials relative to the control group after five and twenty

one days post-treatment. Carrageenan group exhibited a significant increase in the mean value of total protein and amyloid β -protein content in the liver tissue relative to the control group all over the experimental periods while, rats administrated AFA alone or AFA post-carrageenan injection exhibited non-significant change in the mean value of amyloid β -protein and total protein content relative to the control group during the two experimental periods.

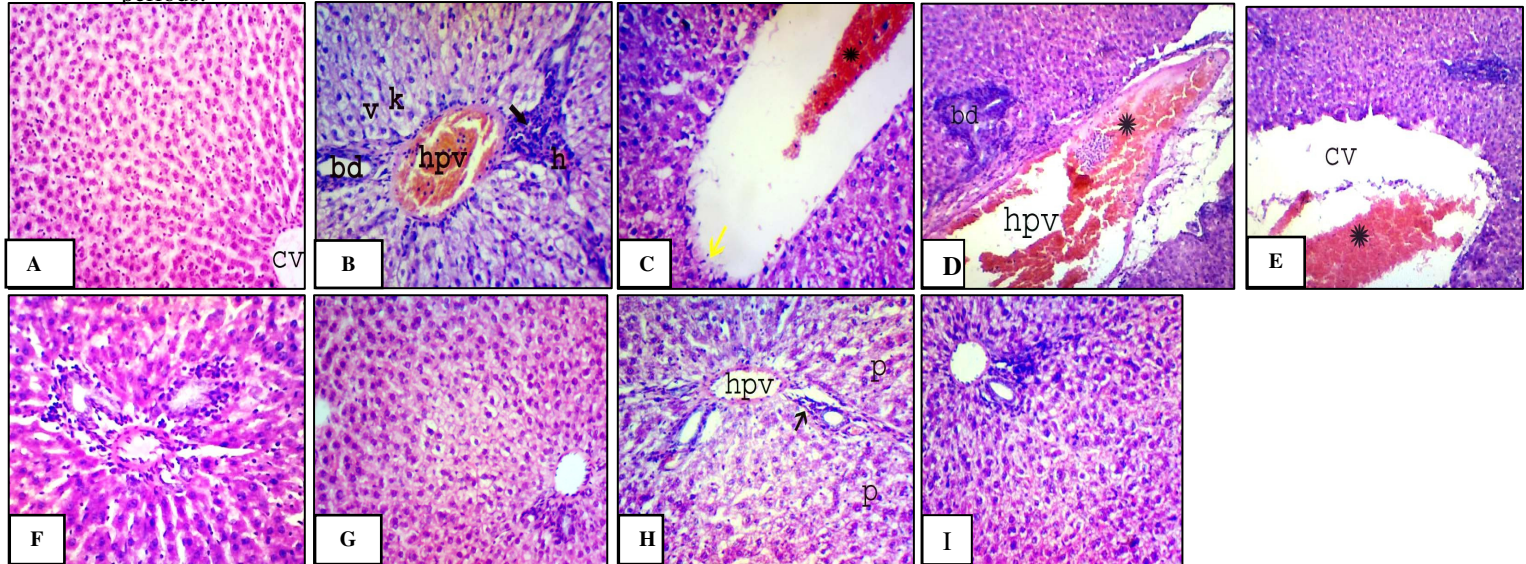


Figure 8- A. A photomicrograph of the liver tissue of the control group showing normal appearance of the central vein (cv), cords of hepatocytes and blood sinusoids. B. A photomicrograph of the liver tissue of rats five days post- carrageenan injection showing highly dilated and congested hepatic portal vein (hpv) which contain hemolysed blood cells inside them, elongated and distorted walls of the bile ducts (bd) with increased proliferation in them, aggregated lymphocytes (→) in and around the portal areas with hemorrhagic area (h), numerous vacuolated hepatocytes (V) and highly increased Kupffer cells (K). C. A photomicrograph of the liver tissue of rats five days post- carrageenan injection showing highly dilated central vein which contains hemolysed blood cells inside it (*) with highly distorted endothelial lining of it (→). D. A photomicrograph of the liver tissue of rats injected with carrageenan and examined after twenty one days showing highly congested and dilated hepatic portal veins (hpv) , they contain hemolysed blood cells inside them (*) with highly stratified walls of bile ducts (bd). E. A photomicrograph of the liver tissue of rats injected with carrageenan and examined after twenty one days showing highly distorted wall of the central vein (CV) with ruptured and delaminated endothelial lining of it. It contains hemolysed blood cells inside it (*). F. A photomicrograph of the liver tissue of rats treated with AFA alone for five days showing normal structure of the portal area. G. A photomicrograph of the liver tissue of rats treated with AFA alone for twenty one days showing somewhat normal architecture of the portal area with increased lymphocytes. H. A photomicrograph of the liver tissue of rats treated with AFA post-carrageenan injection for five days showing somewhat normal structure of most hepatocytes of the portal area, but some hepatocytes contain pyknotic nuclei (P) with slightly increased lymphocytes (→). I. A Photomicrograph of the liver tissue of rats treated with AFA post-carrageenan injection for twenty one days showing well developed portal area.(H&E X200).

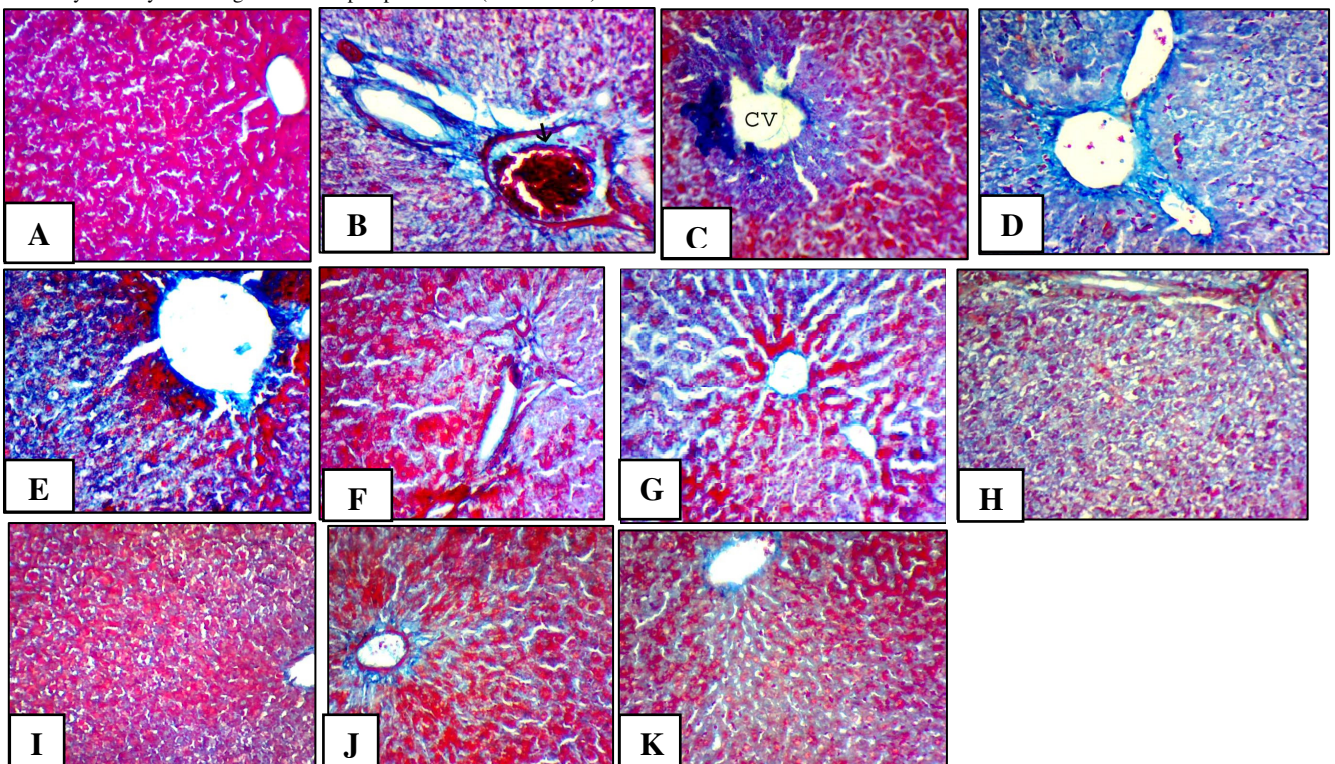


Figure 9- A. A photomicrograph of the liver tissue of the control group showing thin bundles of collagen fibres support walls of the hepatocytes, blood sinusoids and walls of the blood vessels. **B&C.** Photomicrographs of the liver tissue of rats five days post-carrageenan injection showing highly increased collagen bundles around the portal area, inside the hepatic portal veins (→), around the bile ducts and also beside the central vein. **D&E.** Photomicrographs of the liver tissue of rats injected with carrageenan and examined after twenty one days showing highly increased collagen fibres all over the liver tissue especially in walls of the central veins and in the portal area. **F&G.** Photomicrographs of the liver tissue of rats treated with AFA alone for five and twenty one days respectively showing normal distribution of collagen fibres around the hepatocytes, the central vein, portal area and the blood sinusoids. **H&I.** Photomicrographs of the liver tissue of rats treated with AFA post-carrageenan injection for five days showing somewhat normal distribution of collagen fibres around the hepatocytes, central vein, portal area and blood sinusoids. **J&K.** Photomicrographs of the liver tissue of rats treated with AFA post-carrageenan injection for twenty one days showing normal distribution of collagen fibres around the hepatocytes, central vein, portal area and blood sinusoids. (Mallory's trichrome stain X 200).

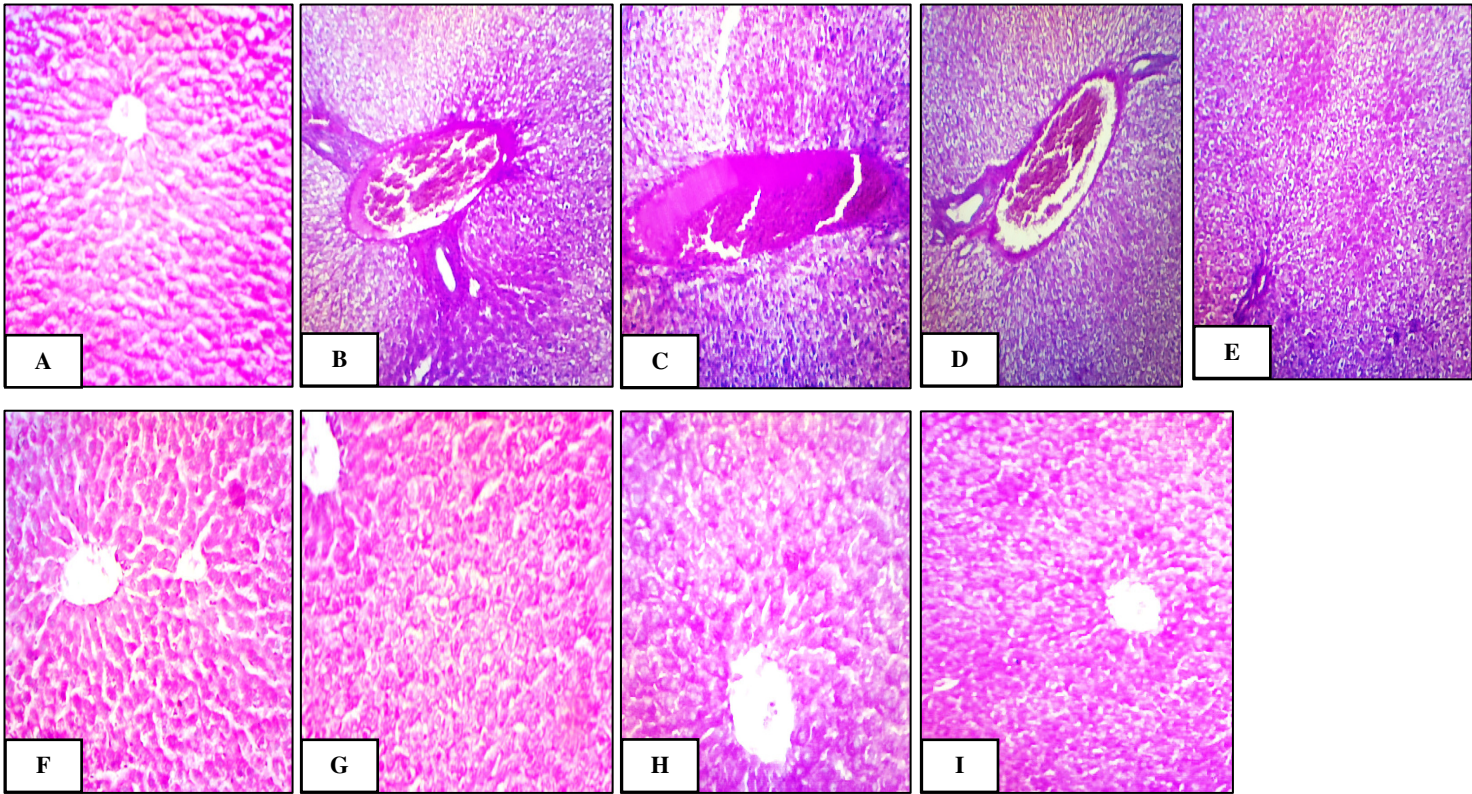


Figure 10- A. A photomicrograph showing normal distribution of PAS +ve materials in the liver tissue of the control group. **B& C.** Photomicrographs showing increased staining affinity of PAS +ve materials in the liver tissue of carrageenan group after five days. **D&E.** Photomicrographs showing increased staining affinity of PAS +ve materials in the liver tissue of carrageenan group after twenty one days. This increase was observed inside and around the highly dilated hepatic portal veins, around walls of the bile ducts and around the hepatocytes. Also, this increase was observed inside and around the highly dilated central vein and in the hemolysed RBCs. **F&G.** Photomicrographs showing normal distribution of PAS +ve materials in the liver tissue of AFA group after five (Fig.F) and twenty one days (Fig.G). **H&I.** Photomicrographs showing somewhat normal distribution of PAS +ve materials in the liver tissue of AFA+ Carr group after five (Fig.H) and twenty one days (I). (PASX200).

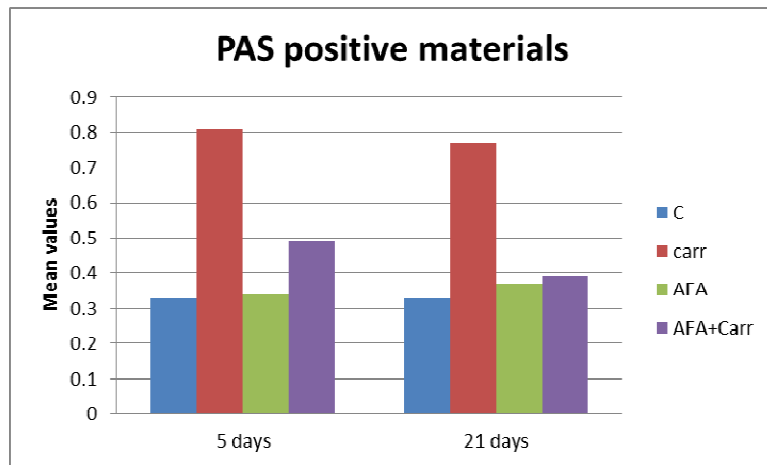


Figure 11- Effect of carrageenan and/ or AFA on the mean optical density values of PAS +ve materials in the liver of adult male albino rats.

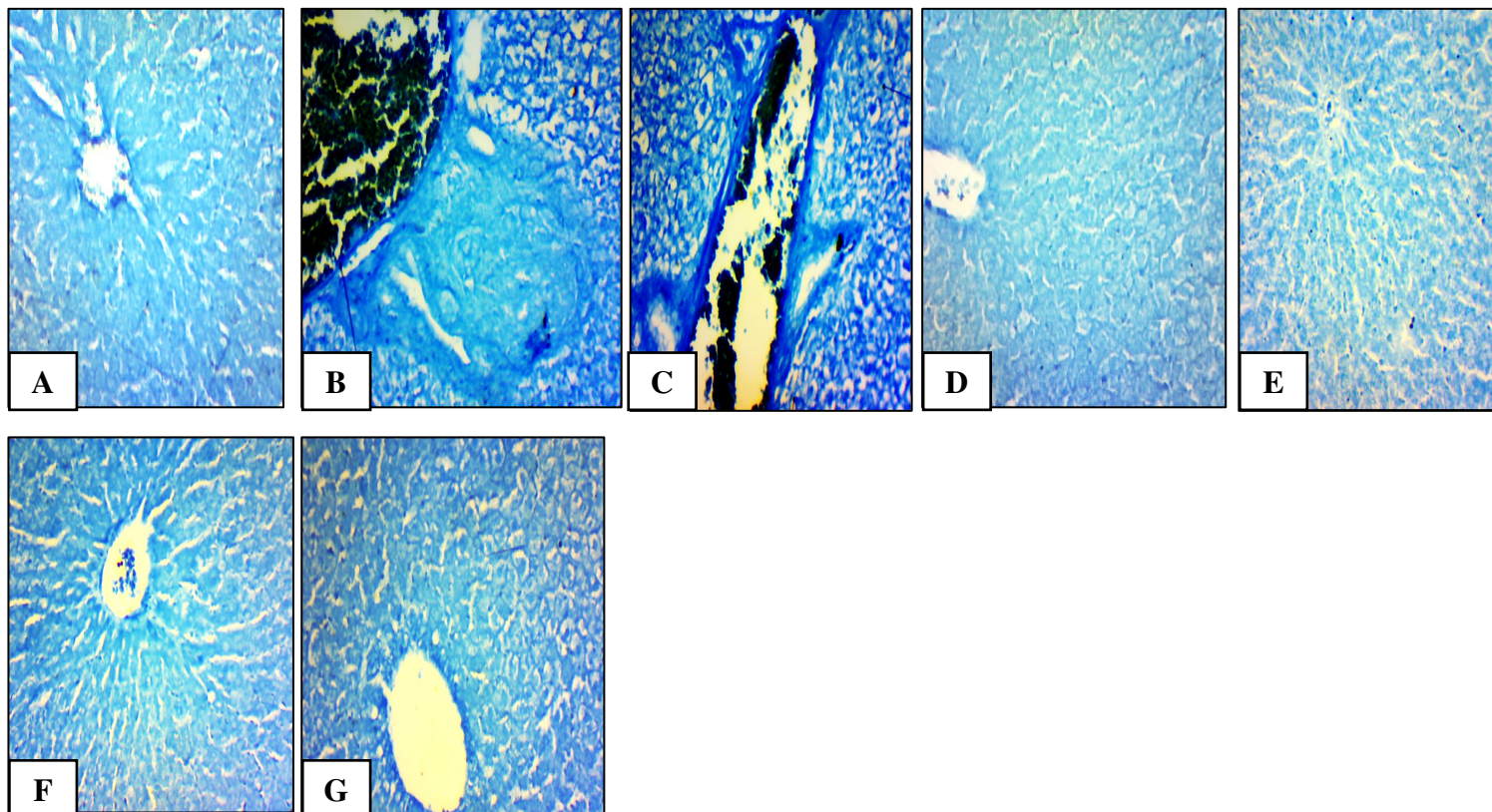


Figure 12- A. A photomicrograph from section of the liver tissue of the control group showing normal protein content in the portal area. **B&C.** Photomicrographs showing densely stained total protein in the liver tissue of carrageenan group (Carr) after five (Fig.B) and twenty one days (Fig.C). This increase was observed around highly dilated and congested hepatic portal veins, elongated and distorted walls of the bile ducts and around the vacuolated hepatocytes. **D&E.** Photomicrographs of sections of the liver tissue of AFA group showing normal protein content all over the liver tissue after five (Fig. D) and twenty one days (Fig.E). **F&G.** Photomicrographs showing somewhat normal distribution of total protein in the liver tissue of AFA+ Carr group after five (F) and twenty one days (Fig.G). (Bromophenol blue X 200).

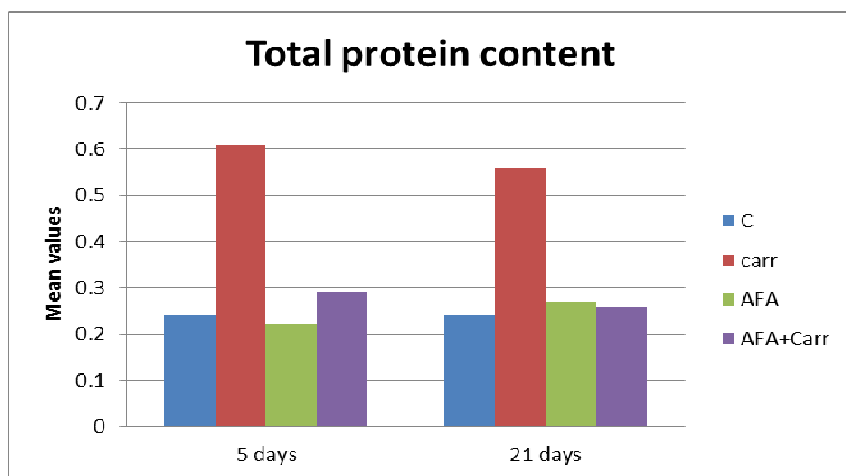


Figure 13- Effect of carrageenan and/ or AFA on the mean optical density values of total protein content in the liver of adult male albino rats.

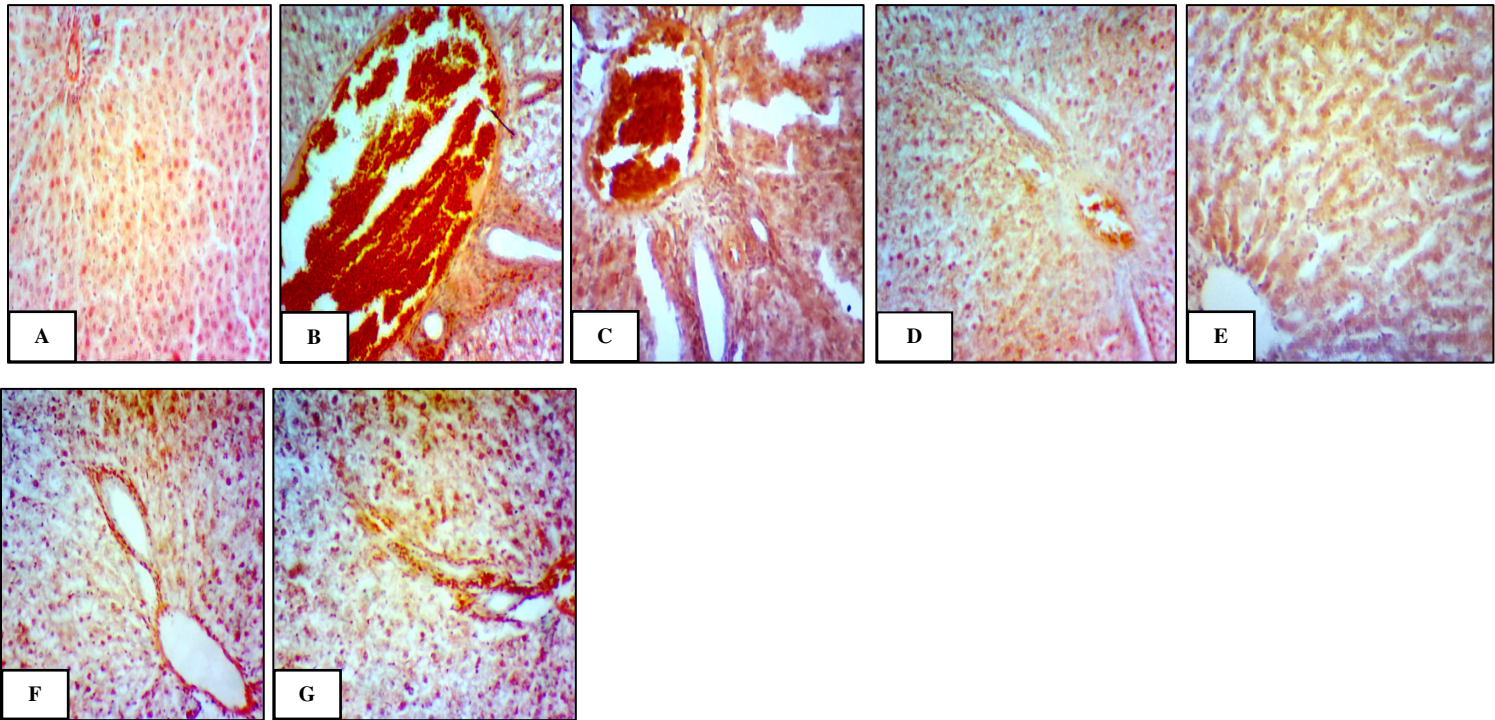


Figure 14- A. A photomicrograph of section of the liver tissue of the control group showing faintly stained amyloid protein. **B&C.** Photomicrographs showing deeply stained amyloid protein in the portal areas of the liver tissue of carrageenan group after five (Fig.B) and twenty one days (Fig.C). This increase was observed inside and around the highly dilated and congested hepatic portal veins, around elongated and distorted walls of the bill ducts. **D&E.** Photomicrographs of sections of the liver tissue of AFA group showing faintly stained amyloid protein all over the liver tissue after five (Fig.D) and twenty one days (Fig.E). **F& G.** Photomicrographs showing somewhat normal distribution of amyloid protein in the liver tissue of AFA+ Carr group after five (Fig.F) and twenty one days (Fig.G). (Congo red stain X 200).

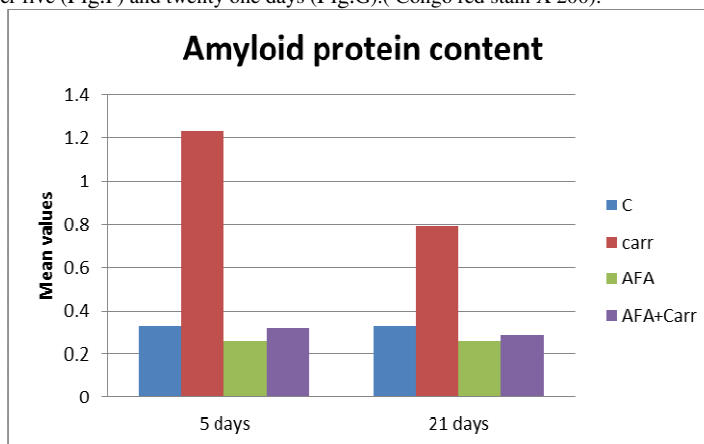


Figure 15- Effect of carrageenan and/ or AFA on the mean optical density values of amyloid β -protein content in the liver of adult male albino rats .

4 Discussion

In the present study, there were significant decreases in the mean values of RBCs, Hb and Hct of rats after five and twenty one days post-carrageenan injection as compared to the control group. These results come in agreement with those of Davidson *et al.* (1981) who reported that intraperitoneally injection of carrageenan (especially kappa and lambda) caused thrombocytopenia and red-cell damage within 2 days. This was followed by rebound thrombocytosis and persistent anemia (within 4

days) accompanied by a reticulocytosis. They also demonstrated that carrageenan exert several and varied effects on the haemopoietic system and its different cell lineages. Abdel-Raouf (2006) demonstrated that the decrease in hemoglobin and RBCs which is known as anemia, may be attributed to the effect of carrageenan on the haemopoietic system. In the present study supplementation of carrageenan injected group with AFA ameliorated the changes in the RBCs count, Hb and Hct. These findings are in agreement with those of Jenesn *et al.* (2001) ; Zhang *et al.* (2001) and Selmi *et al.* (2011) who reported that BGA prevent anemia and many other symptoms of nutritional deficiency because they give the

body many nutrients which difficult to obtain them from other sources. Also, BGA have a stimulatory action on the metabolism of iron and hemoglobin in normal rats, thus reduce the severity of anemia and increase blood hemoglobin concentrations.

Results of the present study showed a significant elevation in white blood cells count of carrageenan injected group as compared to the control group. Similarly, Thomson and Fowler (1981) and Abdel-Raouf (2006) showed that carrageenan acts as a natural chemical substance capable of inducing production or proliferation of total leucocyte count in rats injected with carrageenan. Results of the present study illustrated that supplementation of rats with AFA alone and AFA post-carrageenan injection for twenty one days showed non-significant increase in the leucocytic count. Joshi *et al.* (2002) reported that BGA increased WBC count and this increase can be correlated with increased antibody production. Also, Sharma and Sharma (2005) reported that this stimulatory action of BGA might be attributed to its constituent phycocyanin which regulates the production of white blood cells even when bone marrow stem cells are damaged by toxic chemicals or radiation.

Results of the present study revealed that injection of rats with carrageenan exhibited a significantly increased ALT, AST and ALP activities in serum when compared to the control group; this incidence indicated the liver damage by carrageenan. Significant elevation in liver enzymes after injection with carrageenan come in agreement with the results of Abdel-Raouf (2006) who showed that the liver enzymes (AST, ALT and ALP) were markedly elevated by the injection of carrageenan. The author also added that AST and ALT are intracellular enzymes involved in amino acid and carbohydrate metabolism. Elevation in concentrations of these enzymes in the blood indicated necrosis or disease in the tissue even before clinical symptoms of disease appear (Al-Menoufy, 2002).

The current study revealed that the liver functions have not been affected after oral administration of rats with 94.5 mg/kg of AFA daily for twenty one days as compared to those of the control group. These results go in parallelism with those of Mohamed *et al.* (2014) who showed that there is no significant change in the liver enzyme activities (ALT, AST and ALP) after oral administration of mice treated with 100 mg/kg of BGA (*Aphanizomenon flos-aquae*) for two weeks as compared to those of the normal control group. Treatment of rats with AFA post-carrageenan injection ameliorated the increases in ALT, AST and ALP activity. This comes in agreement with the work of Gini and Kurup (2010) who realized a significant increase in the activity of serum enzymes AST, ALT and ALP in rats administrated paracetamol as compared to the control group. However, the activities of these enzymes were significantly lowered in rats treated with AFA (100 mg/ kg body weight) post-paracetamol administration in comparison with paracetamol administrated group. Furthermore, Sharoud (2015) reported

that the presence of blue pigment phycocyanin in the blue green algae reduced the hepatotoxicity caused by paracetamol. Reduction in the levels of the liver enzymes induced by blue green algae attributed to the inhibition of reaction involved in the formation of reactive metabolites, cirrhosis and its radical scavenging activity.

In the present study examination of the liver tissue after five and twenty one days in the carrageenan injected group of male adult albino rats showed many histopathological alterations such as aggregated lymphocytes in and around the portal areas with hemorrhagic areas, highly dilated and congested hepatic portal veins which contained hemolysed blood cells, distorted wall of the central veins with ruptured and delaminated endothelial lining of them, elongated and distorted walls of the bile ducts which show highly increased proliferation, numerous vacuolated hepatocytes and highly increased kupffer cells.

These results are in agreement with those described previously by Kumar *et al.* (2014) who observed that in carrageenan injected group, the liver tissue showed dilation of the arteries and veins in the portal areas with thickening of the bile ducts epithelium second day post-injection. The hepatocytes were moderately swollen with prominent margins and nuclear karyorrhexis. On the fourth day after the injury, liver tissue showed micro-hemorrhagic spots. They also added that the histopathological study showed marked dilation of arteries and thickening of the bile ducts which revealed that carrageenan may act as a vasodilator. Vasodilation characterized by focal to diffuse hemorrhages in the capillaries of the liver tissue.

Supplementation of rats with AFA post-carrageenan injection showed somewhat normal appearance of the central and portal areas of the liver tissue after five days, but some hepatocytes contained pyknotic nuclei with lymphocytic infiltration in and around the portal area and around the central vein. While, examination of sections of the liver tissue after twenty one days showed improvement of architecture of the liver tissue with well-developed central and portal areas. Karadeniz *et al.* (2008) and Ou *et al.* (2010) concluded that BGA protecting the liver from toxic injury of carbon tetra chloride (CCl₄) and preserving the hepatocyte ultrastructure and suggested that the probable hepatoprotective activity in rats might be due to the following effects: stabilizing the hepatocyte membrane by preventing lipid peroxidation, ameliorating the activities of the antioxidant enzymes, inhibition of the inflammation and the radical scavenging activity. These effects might be attributed to the increased amounts of phycocyanine and phenolic compounds and the antioxidant capacity as confirmed by three different antioxidant activity tests. They also added that phycocyanine could block inflammatory infiltration through its anti-inflammatory activities by inhibiting transforming growth factor-beta1 and hepatocyte growth factor expression. Also, Gini and Kurup (2010) reported that the congestion and inflammatory cell infiltration evoked by acetaminophen was considerably decreased by ethanol extract of AFA

indicating its possible anti-hepatotoxic action. They also added that ethanol extract of AFA prevent hepatic injury by neutralizing oxidative stress. The hepatoprotective effect of AFA may be due to the presence of phycocyanin pigment present in it. Thus the possible mechanism of the hepatoprotective effect of ethanol extract of AFA is due to its antioxidant effect.

The present results are also in agreement with those of Alam *et al.* (2013) who observed that the presence of β -carotene, enzyme superoxide dismutase, vitamins or selenium in blue green algae produced an immunostimulant activities and protective effects against paracetamol – induced liver damage. Also, Abdel-Daim *et al.* (2013) reported that the hepato-protective effect of BGA may be referred to its active components; β -carotene, blue pigment phycocyanin, linolenic acid, sulfated polysaccharide, vitamins (C and E) and selenium which provoke the activity of free radical scavenging enzyme system that render hepatic protection.

Results of the present study showed highly increased collagen fibres in and around the portal areas, inside the hepatic portal vein and also beside the central veins after five and twenty one day's post- carrageenan injection.

Ramadori and Saile (2004) and Saile and Ramadori (2007) showed that hepatic stellate cells produce extracellular matrix and collagen when activated during inflammatory condition. In the current study treatment with AFA alone and AFA post-carrageenan injection showed somewhat normal distribution of collagen fibres around the hepatocytes, around the central veins, in the portal areas and in the blood sinusoids after five and twenty one days.

The obtained results showed that carrageenan group exhibited a significant increase in PAS positive materials all over the experimental periods. While, rats administrated AFA alone or AFA post-carrageenan injection exhibited non-significant increase in PAS positive materials relative to the control group after five and twenty one days post-treatment. Barsanti and Gualteri (2006) showed that AFA like other cyanobacter and plants uses photosynthesis to produce glycogen that is stored and utilized by the cell. While cell walls of plants are mainly cellulose, AFA's cell walls are composed of peptides and carbohydrates, the typical cell wall material of bacteria.

The present results revealed that carrageenan group exhibited a significant increase in the total protein content in the liver tissue relative to the control group all over the experimental periods. Borthakur *et al.* (2012) stated that carrageenan-induced increase in BCL10 protein expression (B-cell leukemia/lymphoma 10) ; total cellular BCL10 protein content remained significantly elevated compared to the control for 24 h after carrageenan withdrawal. One mechanism, proposed by the *in vitro* data, is that carrageenan binds to a membrane receptor known as Toll-Like-Receptor 4 (TLR4) and triggers a signaling cascade resulting in the expression of proinflammatory cytokines (Bhattacharyya *et al.*, 2008a, b). Rats administrated AFA post-carrageenan injection exhibited

non-significant changes in total protein content relative to the control group after five and twenty one days post-treatment. Stengel *et al.* (2011) demonstrated that cyanobacteria contain phycobiliproteins, a group of proteins involved in photosynthesis. Pigments such as phycobilin and phycoerythrin are associated with these proteins and these compounds have been found to have hepatoprotective, anti-inflammatory, immunomodulating, anticancer and antioxidant properties.

The present study showed increased amyloid protein content in the liver tissue of carrageenan group relative to the control group all over the experimental periods. While, treatment with AFA post-carrageenan injection showed somewhat normal deposition of amyloid protein content relative to the control group after five and twenty one days post-treatment. According to Hwang *et al.* (2011) treatment with 200 mg/kg of BGA (*Spirulina*) water extract decreased lipid peroxide and amyloid β -protein deposition in the brain of senescence-accelerated mice.

5 References

- Abdel-Daim MM, Abuzead SMM, Halawa SM (2013). Protective role of *Spirulina platensis* against acute deltamethrin-induced toxicity in rats. PLoS ONE 8(9): e72991. doi:10.1371/journal.pone.0072991
- Abdel-Raouf, O.M. (2006). Impact of an anti-inflammatory drug combined with heat stress on certain haematological, biochemical and histological parameters. Ph. D. Thesis, Zoology Department, Faculty of Science, Al-Azhar University.
- Alam, M.A.; Haider, N.; Ahmed, S.; Alam, M.T.; Aziz, A. and Perveen, A. (2013). Tahlab (*Spirulina*) and few other medicinal plants having anti-oxidant and immunomodulatory properties described in unani medicine- a review. Int. J. Pharmaceut. Sci. Res., 4: 4158-4164.
- Al-Menoufy, G.A. (2002). Effect of repeated administration of some anti-inflammatory drugs on the pathological activity of albino rats. Ph.D. Thesis, Zool. Dep., Faculty of Sc., Cairo University.
- Bancroft, J.D. and Gamble, M. (2002). Theory and Practice of Histological Techniques. 5th ed., Churchill Living Stone. London, pp: 150-152.
- Barsanti, L. and Gualteri, P. (2006). Algae Anatomy, Biochemistry and Biotechnology. C.R.C. Press. London, pp:1467-1471.
- Benedetti, S.; Benvenuti, F.; Pagliarini, S.; Francogli, S.; Scoglio, S. and Canestrari, F. (2004). Antioxidant properties of a novel phycocyanin extract from the blue-green alga *Aphanizomenon flos-aquae*. Life Sci., 75(19):2353-2362.
- Benedetti, S.; Benvenuti, F.; Scoglio, S. and Canestrari, F. (2010). Oxygen radical absorbance capacity of phycocyanin and phycocyanobilin from the food supplement *Aphanizomenon flos-aquae*. J. Med. Food, 13(1):223-227.
- Bhattacharyya, S.; Dudeja, P.K. and Tobacman, J.K. (2008a). Lipopolysaccharide activates NF- κ B by TLR4-

- Bcl10-dependent and independent pathways in colonic epithelial cells. *Amer. J. of Physiol.*, 295:784–790
- Bhattacharyya, S. ; Ravinder, G. ; Chen, M.L.; Zhang, F. ; Linhardt, R.J. ; Dudeja, P.K. and Tobacman, J. K. (2008 b). Toll-like receptor 4 mediates induction of the Bcl10-NF κ B-interleukin-8 inflammatory pathway by carrageenan in human intestinal epithelial cells. *J. Biol. Chem.*, 238:10550–10558.
- Borthakur, A.; Bhattacharyya, S.; Anbazhagan, A.N.; Kumar, A. ; Pradeep, K. ; Dudeja, P.K. ; Joanne, K. and Tobacman, J.K. (2012). Prolongation of carrageenan-induced inflammation in human colonic epithelial cells by activation of an NF κ B-BCL10 loop. *Biochem. Biophys. Acta. Molecul. Basis of* 1822(8):1300-1307.
- Chakdar, H. ; Jadhav, S.D. ; Dhal, D.W. and Pabbi, S. (2012). Potential applications of blue green algae. *J. Sci. Indust. Res.* , 71: 12-30.
- Dacie, J.V. and Lewis, S.M. (1991). *Practical Haematology*. 7th ed., Churchill Livingstone. Edinburgh, pp: 48-52.
- Davidson, R.J.L. ; Avidson, J.G. ; Simpson, P.H. ; Whiting, J.I. ; Milton, J.I. and Thomson, A.W. (1981). Haematological changes following systemic injection of purified carrageenans (Kappa, Lambda and Iota). *Br. J. Exp. Pathol.*, 62: 529-536.
- Drabkin, D.L. and Austin, J.H. (1932). Spectrophotometric studies: Spectrophotometric constant for common hemoglobin derivatives in human, dogs and rabbit blood. *J. of Biolog. Chem.*, 98: 719-725.
- Drury, R. and Wallington, E. (1980). *Carleton's Histological Technique*. 4th ed., Oxford. Univ. Press, New York.
- El- Depsi, S.M. (2016). Evolution of the role of glibenclamid and *Aphanizomenon flos-aquae* extract on some organs of the induced diabetes rats. M.Sc. Thesis, Zoology Department, Faculty of Science, Al-Azhar University.
- Ghosh, A.K.; Hiraswa, N.; Niki, H. and Ohuchi, K. (2000). Cyclo-oxygenase 2 mediated angiogenesis in carrageenan induced granulation tissue in rats. *J. Pharmacol. Exp. Therap.*, 295(2): 802 – 809 .
- Gini, C.K. and Kurup, M.G. (2010). Antioxidant and hepatoprotective activity of *Aphanizomenon flos-aquae* line against paracetamol intoxication in rats. *Indian J. Exper. Bio.*, 48:1123-1130.
- Hwang, J.H. ; Lee, I.T. ; Jeng, K.C.; Wang, M.F. ; Hou, R.C. ; Wu, S.M. and Chan, Y.C. (2011). *Spirulina* prevents memory dysfunction, reduces oxidative stress damage and augments antioxidant activity in senescence-accelerated mice. *J. Nutr. Sci. Vitaminol.*, 57:186–191.
- Jensen, G.S. ; Ginsberg, D.I. and Drapeau, C. (2001). Blue green algae as an immuno- enhancer and biomodulator. *J. Amer. Nutraceut. Assoc.*, 3: 24-30.
- Joshi, P. ; Harish, D. and Bose, M. (2002). Effect of lindane and malathion exposure to certain blood parameters in a fresh water teleost fish *Clarias batrachus*. *Poll. Res.*, 21:55-57.
- Karadeniz, A. ; Yildirim, A. ; Simsek, N. ; Kalkan, Y. and Celebi, F. (2008). *Spirulina platensis* protects against gentamicin-induced nephrotoxicity in rats. *Phytother. Res.*, 22: 1506–1510.
- Kumar, V. ; Kumar, K. ; Raman, R. P. ; Prasad, K.P. ; Roy, S. ; Kumar, S. and Kumar, N. (2014). Haematological and histopathological changes during carrageenan induced acute inflammatory response in laborohita (Hamilton, 1822) fingerlings. *Int. J. Curr. Microbiol. App. Sci.*, 3(7): 794-802.
- Mazia, D. ; Brewer, P.A. and Alfert, M. (1953). The cytochemical staining and measurement of protein with mercuric bromophenol blue. *Biol. Bull.*, 104:57-67.
- Mc-Kim, J.M. (2014). Food additive carrageenan part I: a critical review of carrageenan *in vitro* studies, potential pitfalls and implications for human health and safety. *Crit. Rev. Toxicol.*, 44(3): 211–243.
- Mitruka, B.M. and Rawnsley, H.M. (1977). *Clinical Biochemical and Haematology Reference Values in Normal and Experimental Animals*. New York, Masson Publishing, USA.
- Mohamed, A.H. ; Osman, G.Y. ; Salem, T.A. and Elmalawany, A.M. (2014). The hepatoprotective activity of blue green algae in *Schistosoma mansoni* infected mice. *Exp. Parasitol.*, 145:7-13.
- Nahin, R.L. ; Barnes, P.M. ; Stussman, B.J. and Bloom, B. (2009). Costs of complementary and alternative medicine (CAM) and frequency of visits to CAM practitioners. *Natl. Health Stat. Rep.*, 30(8):1–14.
- Ou, Y. ; Zheng, S. ; Lin, L. ; Jiang, Q. and Yang, X. (2010). Protective effect of C-phycoyanin against carbon tetrachloride-induced hepatocyte damage *in vitro* and *in vivo*. *Chem. Biol. Interact.*, 185(2):94–100.
- Paget, E. and Barnes, M. (1964). Interspecies dosage conversion scheme in evaluation of results and quantitative application in different species. *Evaluat. Drug Activities Pharmacometric*, 1: 160-162.
- Pears, A. (1977): *Histochemistry Theoretical, and Applied*. 3rd ed., Vol. 1. Churchill Livingstone, London.
- Ramadori, G. and Saile, B. (2004). Portal tract fibrogenesis in the liver. *Lab. Invest.*, 84: 153-159.
- Reddy, C.M. ; Bhat, V.B. ; Kiranmai, G. ; Reddy, M.N. ; Reddanna, P. and Madyastha, K.M. (2000). Selective inhibition of cyclooxygenase-2 by C-phycoyanin a biliprotein from *Spirulina platensis*. *Biochem. Biophys. Res. Commun.*, 277 (3): 599–603.
- Regunathan, C. and Wesley, S.G. (2006). Pigment deficiency correction in shrimp broodstock using *Spirulina* as a carotenoid source. *Aquacult. Nutr.*, 12:425–432.
- Rodak, L.C. (1995). Routing testing in haematology. In: *Diagnostic Haematology*. W.B. Saunders Comp. Philadelphia London, Toronto, pp: 128-144.
- Saile, B. and Ramadori, G. (2007). Inflammation damage repair and liver fibrosis role of cytokines and different cell types. *Gastroenterol.*, 45:77-86.
- Schaap, A. ; Rohrlack, T. and Bellouard, Y. (2012). Optical classification of algae species with a glass lab on a chip. *Lab. Chip. J.*, 12:1527-1532.
- Schumann, G. ; Klauke, R. ; Canalias, F. ; Bossert-Reuther, S. ; Franck, P.F. and Gella, F.J. (2002). IFCC primary reference procedures for the measurement of

catalytic activity concentrations of enzymes at 37 C. Clin. Chem. Lab. Med., 40(7):718-724.

Scoglio, S.; Benedetti, Y.; Benvenuti, F.; Benedetti, S. and Benedetti, S. (2014). Selective monoamine oxidase B inhibition by an *Aphanizomenon flos-aquae* extract and by its constitutive active principles phycocyanin and mycosporine-like amino acids. Phytomedicine, 21(7):992-997.

Scoglio, S.; Benedetti, S.; Canino, C.; Santagni, S.; Rattighieri, E.; Chierchia, E.; Canestrari, F. and Genazzani, A.D. (2009). Effects of a 2-month treatment with Klamina, a Klamath algae extract, on the general well-being, antioxidant profile and oxidative status of postmenopausal women. Gynecolog. Endocrinol., 25: 235-240.

Selmi, C.; Leung, P.S.; Fischer, L.; German, B.; Yang, C.Y.; Kenny, T.P.; Cysewski, G.R. and Gershwin, M.E. (2011). The effects of *Spirulina* on anemia and immune function in senior citizens. Cell Mol. Immunol., 8:248-254.

Sharma, S. and Sharma, S. (2005). Protective role of *Spirulina* feed in a fresh water fish (*Poecilia reticulata*) exposed to an azo dye-methyl red. Indian J. Exp. Biol., 43: 1165-1172.

Sharud, M.N.M. (2015). Protective effect of *Spirulina* against paracetamol induced hepatic injury in rats. J. Exp. Biol. Agricul. Sci., 3(1):34-44.

Singh, S.; Kate, B.N. and Banerjee, U.C. (2005). Bioactive compounds from cyanobacteria and microalgae: an overview. Crit. Rev. Biotechnol., 25:73-95.

Sini, J.M.; Yaro, A.H.; Ayanwuyi, L.O.; Aiyelero, O. M.; Mallum, S.M. and Gamaniel, K.S. (2010). Anti-nociceptive and anti-inflammatory activities of the aqueous extract of the root bark of *Combretum sericeum* in rodents. African J. Biotechnol., 9: 8872-8876.

Snedecor, W.G. and Cochran, G.W. (1980). Statistical Method. 7th edition. Iowa State University Press, Ames., pp: 66-71.

Stengel, D.B.; Connan, S. and Popper, Z.A. (2011). Algal chemodiversity and bioactivity: sources of natural variability and implications for commercial application. Biotechnol. Advanc., 29(5):483-501.

Thomson, A.W. (1981). Haematological changes following systemic injection of purified carrageenans (Kappa, Lambda and Iota). Br. J. Exp. Pathol., 62: 529-536.

Thomson, A.W. and Fowler, E.F. (1981). Carrageenan: a review of its effect on the immune system. Agents Action, 1: 265-273.

Tiniakos, D.G.; Vos, M.B. and Brunt, E.M. (2010). Nonalcoholic fatty liver disease: pathology and pathogenesis. Ann. Rev. Pathol., 5:145-171.

Valle, S. (1986). Special stains in microwave oven. J. Histotechnol., 9:237-248.

Venkatesan, S.; Pugazhendy, K.; Meenambal, M.; Sangeetha, D.; asantharaja, C.V.; Jayachandren, K. and Prabakaran, S. (2012). Protective role of *Spirulina* on the variation of haematological parameter induced by herbicide atrazine in the fresh water fish *Cyprinus carpio* (Linn). Int. J. Pharm. Biol. Arch., 3:249-254.

Weiner, M.L. (2014). Food additive carrageenan, Part II: a critical review of carrageenan *in vivo* safety studies. Crit. Rev. Toxicol., 44(3):244-269.

Yang, Y.; Park, Y.; Cassada, D.A.; Snow, D.D.; Rogers, D.G. and Lee, J. (2011). *In vitro* and *in vivo* safety assessment of edible blue-green algae, *Spirulina plantensis*. Food Chem. Toxicol., 49(7):1560-1564.

Yeh, G.Y.; Davis, R.B. and Phillips, R.S. (2006). Use of complementary therapies in patients with cardiovascular disease. Am. J. Cardiol., 98:673-680.

Young, D. and Friedman, R. (2001). Effects of Disease on Clinical Laboratory Tests. 4th Edition, A.A.C.C. Press, Washington, USA.

Zhang, H.Q.; Lin, A.P.; Sun, Y. and Deng, Y.M. (2001). Chemo- and radioprotective effects of polysaccharide of *Spirulina platensis* on hemopoietic system of mice and dogs. Acta. Pharmacol. Sin., 22: 1121-1124.